

JCP

JOURNAL
OF CLINICAL
PATHOLOGY

JCPJ
CPJCF
JCPJ
CPJCF
JCPJ
CPJCF
JCPJ
CPJCF
JCPJ
CPJCF

July 1999 Vol 52 No 7

Leaders

- 481 Diagnostic and prognostic implications of the unfolding molecular biology of bone and soft tissue tumours J F Graadt van Roggen, J V M G Bovée, J Morreau, P C W Hogendoorn
- 490 Legal and ethical aspects of the vegetative state S A M McLean

Papers

- 494 Is the international normalised ratio (INR) reliable? A trial of comparative measurements in hospital laboratory and primary care settings F D R Hobbs, D A Fitzmaurice, E T Murray, R Holder, P E Rose, J L Roper
- 498 Reliable high risk HPV DNA testing by polymerase chain reaction: an intermethod and intramethod comparison M V Jacobs, P J F Snijders, F J Voorhorst, J Dillner, O Forstlund, B Johansson, M von Knebel Doeberitz, C J L M Meijer, T Meyer, I Nindl, H Pfister, E Stockfleth, A Strand, G Wadell, J M M Walboomers
- 504 Infrequent loss of heterozygosity of APC/MCC and DCC genes in gastric cancer showing DNA microsatellite instability D-C Fang, J R Jass, D-X Wang, X-D Zhou, Y-H Luo, J Young
- 509 Ablation treatment for Barrett oesophagus: what depth of tissue destruction is needed? R Achroyd, N J Brown, T J Stephenson, C J Stoddard, M W R Reed
- 513 Clinicopathological features of serrated adenoma of the colorectum: comparison with traditional adenoma T Matsumoto, M Mizuno, M Shimizu, T Manabe, M Iida
- 517 Ki-67, oestrogen receptor, and progesterone receptor proteins in the human rete ovarii and in endometriosis M S Khan, A R Dodson, M K Heatley
- 521 Reactive and neoplastic lymphocytes in human bone marrow: morphological, immunohistological, and molecular biological investigations on biopsy specimens S M Kröber, H-P Horny, A Greschniok, E Kaiserling

Origins

- 527 Haematoxylin—from the wood R T Allison

Short reports

- 529 Adherence of *Candida albicans* to oral epithelial cells differentiated by Papanicolaou staining D W Williams, R Walker, M A O Lewis, R T Allison, A J C Potts
- 532 Pseudoglandular formations in clot sections from fine needle aspirates—an artefact caused by bubble formation during aspiration C E Keen, A Karim
- 535 Malignant mesothelioma eight years after a diagnosis of atypical mesothelial hyperplasia J Scurry, M A Duggan
- 538 Extension of extramammary Paget disease of the vulva to the cervix J Lloyd, D J Evans, A M Flanagan
- 541 A case of sudden death caused by fibromuscular dysplasia K M Ropponen, I Alafuzoff
- 543 Polypoid uterine lesions mimicking endometrial stromal sarcoma W G McCluggage, J M Alderdice, M Y Walsh
- 547 Development of a calcifying fibrous pseudotumour within a lesion of Castleman disease, hyaline-vascular subtype J L Dargent, J Delplace, C Roufousse, J P Laget, L Lespagnard

Letters

- 550 Methods for analysing AgNORs K Metze, I L-Metze
- 550 Cervical intraepithelial glandular neoplasia M K Heatley, A A-nafussi

Miscellanea

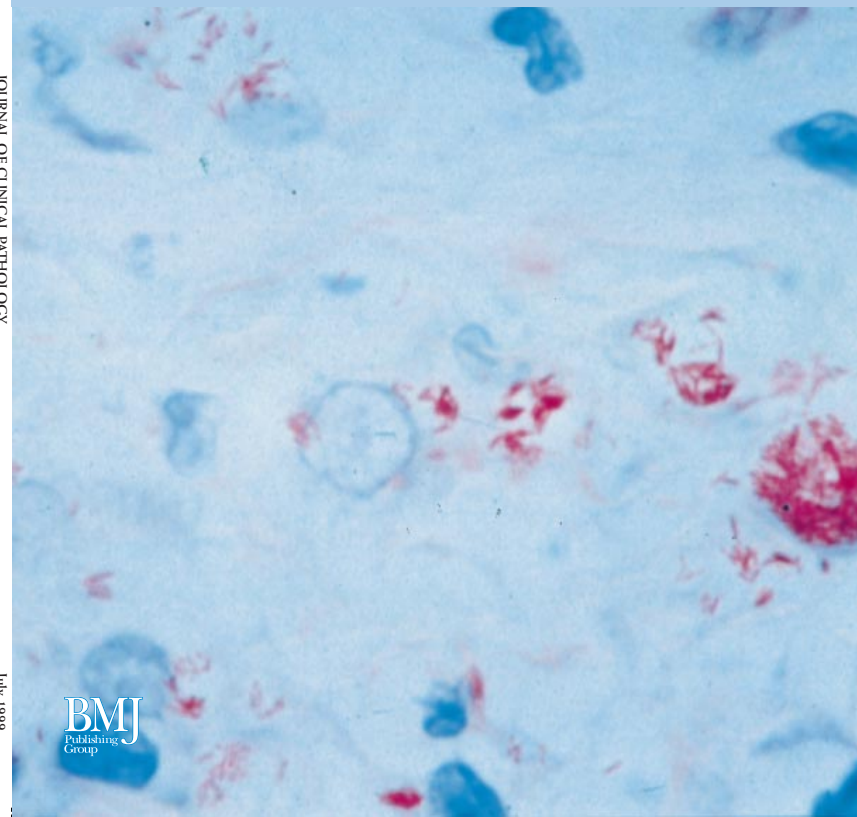
- 550 Book reviews • Instructions for authors • Best practice articles
- 508 *Molecular Pathology*, contents

JCP

JOURNAL OF CLINICAL PATHOLOGY

The Journal of the Association of Clinical Pathologists

Vol 52 No 7 Pages 481-532 July 1999



BMJ
Publishing
Group