

Correspondence

Mature renal teratoma and a synchronous malignant neuroepithelial tumour of the ipsilateral adrenal gland

The main primary childhood renal neoplasms are nephroblastoma, mesoblastic nephroma, clear cell sarcoma, and rhabdoid tumour. Other primary renal neoplasms include primitive neuroectodermal tumour (PNET), renal cell carcinoma, and angiomyolipoma. Nephroblastoma is the most common renal tumour in children. It is a complex embryonal tumour of metanephric blastemal derivation, which often contains diverse epithelial and stromal tissues. Diagnostic problems are often encountered when tumours contain a variety of heterologous elements. The term teratoid nephroblastoma has been used to describe a variant of nephroblastoma with a predominance of heterologous tissues.¹ It is this variant that can be confused with a teratoma. Renal teratomas are rare and most have been dismissed as cases of teratoid nephroblastomas or retroperitoneal teratomas secondarily invading the kidney.² The differentiation between these two neoplasms in the kidney is often problematic.

Neurogenic tissues in the kidney can be found in primary tumours or as part of metastatic tumours. The primary tumours are nephroblastoma, which may contain ganglion cells, neuroblast, and neuroglial tissue,² and PNET.^{3,4} Adrenal neuroblastomas can directly invade the adjacent kidney.⁵ We describe the pathology of a right renal mass in a 3 year old child and discuss the differential diagnosis.

A 3 year old girl presented with abdominal pain and diarrhoea. On examination she was found to have signs of pulmonary tuberculosis and was started on antituberculous treatment. Subsequently, a large, firm, tender, right flank mass clearly separate from the liver was detected and she was referred to the Regional Paediatric Surgical Unit for further investigation and management.

On admission, the child was apyrexial, emaciated, and weighed 13 kg. She had bilateral coarse crackles and a wheeze. The abdomen was distended and a non-tender 3 cm hepatomegaly was palpated. Furthermore, a 10 × 12 cm non-tender, firm, non-pulsatile right flank mass was detected.

Results of routine laboratory tests were as follows: haemoglobin, 90 g/litre (normal, 112–143); white blood cell count, 8.2×10^9 /litre (normal, 5.5–15.5); and platelet count, 224×10^9 /litre. Urinary catecholamine values were as follows: noradrenaline, 0.279 μ M/mM creatinine (CRT) (normal, 0–0.08); adrenaline, 0.023 μ M/mM CRT (normal, 0–0.035); dopamine, 0.67 μ M/mM CRT (normal, 0–1.13); vanillylmandelic acid 9 μ M/mM CRT (normal, 0–15); and homovanillic acid, 11 μ M/mM CRT (normal, 0–15). Renal and liver function tests were normal.

Computed tomography (CT) scan of the abdomen revealed a large tumour involving the right side of the abdomen. There were also multiple hepatic lesions consistent with metastases. A fine needle aspiration biopsy of the mass was performed. After a cytological

diagnosis of neuroblastoma the child was started on the appropriate chemotherapy protocol consisting of vincristine, actinomycin, cyclophosphamide, and adriamycin. She suffered seizures while on chemotherapy, which was subsequently decreased to 75% dosage. A CT scan of the brain was normal.

The child died two weeks after commencement of chemotherapy. A necropsy was performed.

Necropsy revealed an enlarged right kidney measuring 16 × 10 × 8 cm and weighing 1200 g. There was a well demarcated tumour mass in the upper pole of the kidney, which measured 7 × 6.5 × 5 cm (fig 1). The upper pole mass was encapsulated (fig 1; arrows), predominantly firm in consistency, and had yellow and white areas. There was a small area of soft, friable tumour present within the mass, close to the junction of the adjacent kidney. On the capsular surface the upper pole mass was clearly demarcated from the remaining kidney. It was not possible to recognise normal renal tissue because the remaining kidney was diffusely swollen, pale, soft, and contained focal areas of necrosis (fig 1). The right adrenal gland was not identified despite serial sectioning. There was extension of the tumour into the right renal vein and inferior vena cava. Tumour spread into the ureter was also present. There were multiple greatly enlarged para-aortic lymph nodes containing metastatic tumour. Metastatic tumour deposits were present in the liver, vertebrae, and both lungs. In addition, caseous nodules were identified in the lungs and hilar lymph nodes. The left kidney and adrenal gland were normal. The rest of the postmortem examination was normal.

Histological examination of the well demarcated upper pole mass showed a tumour composed of multiple heterologous tissue elements. Tissues derived from all three germ layers—ectoderm, mesoderm, and endoderm—were present. The yellow areas corresponded to mature adipose tissue microscopically. In addition, striated muscle, smooth muscle, and fibrous tissue were present, as were small islands of neuroglial

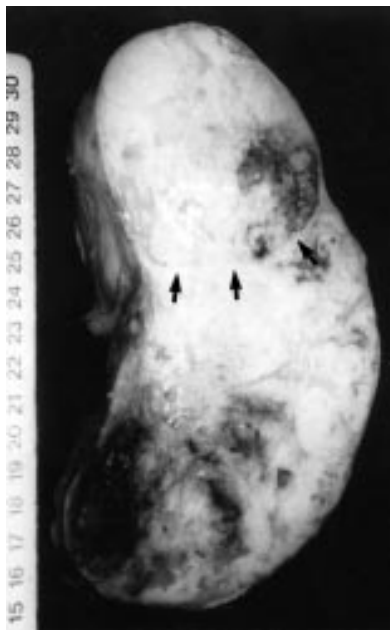


Figure 1 An enlarged right kidney with an encapsulated tumour mass (arrows) in the upper pole. The rest of the kidney is also diffusely infiltrated.

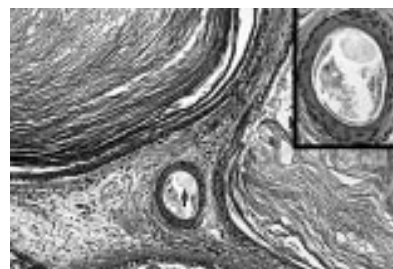


Figure 2 Keratinous cysts, hair follicle containing hair shaft (arrow), and adjacent adipose tissue. Inset: hair follicle with hair shaft.

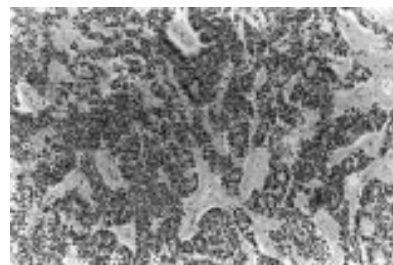


Figure 3 Malignant neuroepithelial tumour with focal neuroectodermal canals and rosettes.

tissue. The epithelial component was variable and consisted of small tubular structures lined by cuboidal epithelial cells with clear cytoplasm. Also present were larger cystic structures lined by respiratory epithelium. Adjacent to these cysts were small closely packed acini composed of mucin containing epithelium. A prominent feature was the presence of several cysts lined by keratinising stratified squamous epithelium with hair follicles and hair shafts (fig 2). Small round tumour cells diffusely infiltrated the remaining kidney. These were arranged predominantly in solid sheets, but focal neuroectodermal canals and rosettes were also identified (fig 3). In addition, there was microscopic evidence of metastases in the lungs, liver, ovaries, and vertebrae. The metastatic tumour in all sites consisted of the primitive small, round cell component. Sections taken from the region of the right adrenal gland showed a diffuse infiltrate of small round blue cells, but no residual adrenal gland tissue was identified. There were no nephrogenic rests in the kidney.

A panel of immunohistochemical stains was performed on the small cell malignant tumour to detect cytokeratins (AE1/AE3, CAM5.2), synaptophysin, neurone specific enolase (NSE), chromogranin, WT1, desmin, muscle specific actin, S100 protein, glial fibrillary acidic protein, O13, leucocyte common antigen, and epithelial membrane antigen. The small round cells showed immunoreactivity for NSE, synaptophysin, and chromogranin. The cells were non-reactive for the remaining markers.

Histology confirmed tuberculosis of the lungs and lymph nodes. Acid fast bacilli were identified.

To diagnose a renal teratoma, the primary tumour should be unequivocally of renal origin and the tumour should exhibit unequivocal heterotopic organogenesis clearly recognised as evidence of attempts to form organs other than the kidney.² It is the second criterion that often presents a problem. The question is: what constitutes unequivocal organogenesis? The presence of bone, cartilage, muscle, fat, neuroglial tissue, and mature epithelium cannot on their own be regarded as

evidence of organogenesis. Indeed, all of these tissues can be present in both teratomas and teratoid nephroblastomas. In mature teratomas, skin with the dermal appendages, bronchial structures with bronchial glands and cartilage, brain (neuroglial tissue), and teeth are commonly present, and regarded as evidence of organogenesis.

Those neuroblastomas that are characterised by the presence of neuropil and ganglion cells can be readily differentiated from PNET. It is the undifferentiated neuroblastoma, in which neuropil and ganglion cells are sparse or absent, that is sometimes difficult to differentiate from PNET. The immunohistochemical profile and cytogenetics are helpful in this instance. PNET characteristically demonstrates diffuse membrane positivity with O13 (mic2 gene product) and is also immunoreactive for vimentin, cytokeratin, and NSE.⁶ Another highly characteristic feature of PNET/Ewing's sarcoma is the presence of a specific reciprocal translocation: t(11;22)(q24;q12).⁷

Our case presents a unique constellation of pathological features, which pose a diagnostic problem. The well circumscribed encapsulated upper pole mass could be interpreted either as a renal teratoma or a teratoid nephroblastoma. After much deliberation and consultation, we prefer the diagnosis of a primary intrarenal teratoma. Most of the heterologous elements present can, as alluded to earlier, occur in a nephroblastoma. The presence of hair shafts is evidence of terminal differentiation, which is seen in teratomas. Although structures resembling hair follicles have been described in nephroblastoma, to the best of our knowledge hair shafts have not been described in nephroblastoma.

The small round cell tumour presents a more difficult problem. We have demonstrated neural differentiation in these cells with immunoreactivity to NSE, synaptophysin, and chromogranin. It is also quite clear on morphology and immunohistochemistry that this component represents a malignant neuroepithelial neoplasm. The problem however is the derivation or origin of this component. First, it might be a primitive neuroepithelial component arising from the teratoma, a phenomenon that is known to occur. However, we consider this unlikely because the mature teratoma was well circumscribed and not diffusely infiltrated by the neuroepithelial component. Furthermore, there is no evidence of merging of the mature and immature components. Second, it might be a PNET of the kidney. The negative O13 immunoreactivity and the diffuse infiltrative nature of the tumour makes PNET less likely. Cytogenetic studies for the characteristic t(11;22) translocation were not done in this case. Finally, the inability to identify the ipsilateral adrenal gland and the extensive extrarenal tumour in the region of the adrenal gland must be deemed important. We feel that the most plausible explanation is an undifferentiated neuroblastoma of the adrenal gland with permeation of the kidney. The incidence of renal parenchymal invasion by neuroblastoma has been reported to be as high as 20.4% in one series.³ This same study found that invasion of the kidney occurred more frequently with undifferentiated neuroblastomas and those with extensive abdominal involvement.

In trying to clarify the definition of "unequivocal organogenesis", the concept of mimicry in embryonal tumours needs considering. Clearly, mimicry refers to structures or

tissue resembling the normal developmental stages in organogenesis. Therefore, unequivocal organogenesis could be defined as the presence of immature or mature tissues arranged in a manner that is comparable to the "normal" development of the organ or the mature appearance of that organ. If—for example, structures resembling hair follicles and sweat glands are present, but do not demonstrate their normal arrangement in skin, then this should be referred to as mimicry rather than evidence of unequivocal organogenesis. In our case, hair shafts are regarded as evidence of the end stage of differentiation. The cysts lined by squamous epithelium (epidermis) with eccrine sweat glands, hair follicles, and hair shafts warrant classification as a renal teratoma.

The pathological features were finally interpreted as representing two distinct neoplasms: a mature renal teratoma and a malignant neuroepithelial tumour. The latter is probably an undifferentiated neuroblastoma arising in the adrenal gland and invading the kidney, mainly along the hilum.

Our case posed a problem often faced by pathologists who regularly examine renal tumours in children. Furthermore, it highlights the need for a refinement of the diagnostic criteria for renal teratoma. We believe that the differentiation between these two neoplasms must lie in their respective genetics. For example, deletion of the short arm of chromosome 11 should favour a nephroblastoma, as would the presence of nephrogenic rests.

We thank Professor LP Dehner, St Louis, USA for reviewing the histology.

D GOVENDER
L M NTEENE
R CHETTY

Division of Anatomical Pathology, School of Pathology and Laboratory Medicine, University of Natal Medical School, Private Bag 7, Congella, Durban 4013, South Africa
govendh@med.und.ac.za

G P HADLEY
Department of Paediatric Surgery, University of Natal Medical School

- Variend S, Spicer RD, Mackinnon AE. Teratoid Wilms' tumor. *Cancer* 1984;53:1936–42.
- Beckwith JB. Wilms' tumor and other renal tumors of childhood: a selective review from the National Wilms' Tumor Study Pathology Center. *Hum Pathol* 1983;14:481–92.
- Marley EF, Liapis H, Humphrey PA, et al. Primitive neuroectodermal tumor of the kidney—another enigma: a pathologic, immunohistochemical, and molecular diagnostic study. *Am J Surg Pathol* 1997;21:354–9.
- Parlorio E, Arrazola J, Pedrosa I, et al. Primitive neuroectodermal tumor of the kidney. *Am J Roentgenol* 1998;171:1432–3.
- Albregts AE, Cohen MD, Galliani CA. Neuroblastoma invading the kidney. *J Pediatr Surg* 1994;29:930–3.
- Dehner LP. Primitive neuroectodermal tumor and Ewing's sarcoma. *Am J Surg Pathol* 1993;17:1–13.
- Whang-Peng J, Triche TJ, Knutsen T, et al. Chromosome translocation in peripheral neuroepithelioma. *N Engl J Med* 1984;311:584–5.

Random, chance, or hazard?

The recent correspondence exchanged between Dr Batman¹ and Dr Carter and colleagues (*ibid*) airs the issue of the use of the expression "random", which is usually invoked to describe the approach to selecting fields or structures under the microscope for quantification. Having been initiated (from a research perspective) within the "post-Nick Wright" incarnation of the cell kinetics group

in Newcastle during the 1980s, I was heavily influenced (you might say subdued) by the statistical austerity of Dr D Appleton. His view was that what all of us were doing, in choosing areas to quantify, was never really random and I doubt that much has changed across most pathological research. To be truly random the investigator would have to define and assign coordinates to all the suitable fields/structures within the area represented in the slide, number them, and then use a source of random numbers to make an unbiased selection. In practice, what most people do (including, I suspect, Dr Carter and colleagues) is to select by a more haphazard or chance strategy, which most of us never properly define. Dr Appleton (from the benefit of a good Scottish education) suggested that the most appropriate expression would be "selected at hazard", which I did slip by various editors a few times. Having moved on, whenever I try to put this in a paper now my co-authors always strike it out and substitute "selected randomly"; presumably they think it sounds more scientific or less prone to bias. Even I would balk at admitting to selection "by chance". I have no doubt the statistical literature in relation to biology must contain the answer to this issue but I have not found it. I admit to no great diligence in my search. Perhaps some of your readers could point us in the right direction. In practice, the issue probably illustrates the gut feeling that most investigators have, when undertaking quantitative morphology, that statistical rectitude is not always superior to common sense. Common sense suggests that I am unwise to take as an example work from my new colleagues in Sheffield to make these observations but I am sure they are of a forgiving nature.

P G INCE
Department of Neuropathology, 'E' Floor, Medical School, Beech Hill Road, Sheffield S10 2JR, UK

- Batman P. Re: Intra-alveolar haemorrhage in sudden infant death syndrome: a cause for concern? *J Clin Pathol* 2000;53:484.

Thrombophilia testing: science or medicine?

Dr Murphy¹ supports a more discriminate approach to thrombophilia testing than I describe in my own practice² and points out that my opinion is at variance with British Committee for Standards in Haematology (BCSH) guidelines. In respect of the latter, these guidelines were not evidence based and were published 10 years ago. Dr Murphy identifies the main indications for thrombophilia testing from the guidelines as: (1) patients with venous thromboembolism before the age of 45 years, (2) recurrent venous thrombosis or thrombophlebitis, (3) thrombosis in an unusual site, and (4) a first venous thromboembolic event with a clear history of venous thrombosis. Applying current criteria for graded recommendations on levels of evidence these indications would be classified as grade C based on level IV evidence.³ The haemostasis and thrombosis task force for the BCSH is currently preparing an updated guideline on the investigation and management of heritable thrombophilia. This guideline will be evidence based. However, given the lack of randomised clinical trials only grade B recommendations at best will be possible. I share Dr Murphy's concern regarding limited health care resources and

the cost effectiveness of a practice for which there are no current grade A recommendations.

The important issue that Dr Murphy raises relates to why thrombophilia tests are performed; are they to explain why an individual develops venous thromboembolism or are they to optimise clinical decisions? In other words, are they for the sake of science or medicine. If testing is performed to explain why an individual develops thrombosis then the discriminate approach suggested by the 1990 guidelines quoted by Dr Murphy will increase the proportion of tested patients who are found to have a laboratory abnormality.⁴ However, if testing is performed to optimise clinical decisions then there is no rational basis for such a recommendation given the data that are currently available. There is no evidence that the predictive value of thrombophilia testing is in any way superior in the categories of patients outlined above to that in other patients with venous thromboembolism. For example, a patient with a first event after the age of 45 years in the absence of a family history might still be at risk of recurrence in the future. Therefore, the issue is whether testing patients with venous thromboembolism for laboratory evidence of thrombophilia has predictive value. The presence of a raised titre of anticardiolipin antibodies indicates a higher risk of early recurrence and therefore might be considered an indication for continued anticoagulation (grade B). Because lupus anticoagulant activity is also indicative of antiphospholipid activity it might also be considered an indication for continued anticoagulation.⁵ The predictive value of testing for heritable thrombophilia is also becoming clearer as I indicated in my leader. There is no evidence to support a higher intensity or extended duration of anticoagulation in most patients with laboratory evidence of heritable thrombophilia. Exceptions might be patients with homozygous or combined heterozygous defects (grade B). In my own practice I find testing valuable for assessing risk in family members, particularly females patients who are considering pregnancy or oestrogen/progestagen contraceptive pill use. If a thrombophilic defect has been detected in the symptomatic index family member then that specific defect can be looked for in the relatives who are requesting counselling. This obviates the need for an expensive comprehensive screen in all of the family members and avoids confusion as to whether an abnormal result is relevant or not.

Like all clinicians responsible for the judicious use of scarce health care resources Dr Murphy has to decide whether thrombophilia test results influence his clinical practice. If they don't then there is no necessity to do them.

T BAGLIN

Department of Haematology, Addenbrook's NHS Trust, Cambridge, CB2 2QQ, UK
tpb20@cam.ac.uk

- Murphy TP. Thrombophilia testing [letter]. *J Clin Pathol* 2000;53:803.
- Baglin T. Thrombophilia testing: what do we think the tests mean and what should we do with the results? *J Clin Pathol* 2000;53:167-70.
- British Committee for Standards in Haematology. Guidelines on oral anticoagulation: third edition. *Br J Haematol* 1998;101:374-87.
- Mateo J, Oliver A, Borrell M, et al. Laboratory evaluation and clinical characteristics of 2,132 consecutive unselected patients with venous thromboembolism—results of the Spanish multicentric study on thrombophilia (EMET study). *Thromb Haemost* 1997;77:444-51.

- Greaves M. Antiphospholipid antibodies and thrombosis. *Lancet* 1999;353:1348-53.

Book reviews

Illustrated Pathology of the Spleen. Wilkins B, Wright D. (£65.00.) Cambridge University press, 2000. ISBN 0 521 62227 1.

Illustrated Pathology of the Spleen by Bridget Wilkins and Dennis Wright is a beautiful book. It is a pleasure to hold it and browse through it because of its size, layout, and the quality of the print and figures. But that is only the exterior. At least equally important is the contents. These match the style.

The authors aim with this book to demystify the spleen by putting forward a systematic, analytical approach to the interpretation of splenic pathology. The authors succeed by using numerous illustrations and the book is indeed a combination of an atlas and a textbook.

The book is well written and very readable. Most textbooks are reference works where one can look up a specific problem. This book is also a guide. The problem with splenic pathology is where to start, what to look for. The first two chapters ("Introduction" and "Normal structure, development and functions of the spleen") serve as a firm basis on which the approach to the study of splenectomy specimens is built. The last chapter ("Summary: some key points in splenic differential diagnosis") provides an easy approach for some common situations. These three chapters include about 50 pages of text and illustrations and the evening it will cost studying them is a worthwhile investment. The other chapters deal with the disorders expected in the spleen, such as haematopoietic and infectious diseases, but there is also a chapter on post-traumatic and incidentally removed spleens, illustrating the practical approach of the authors.

Are there no complaints? Of course there are a few points that can be made. Not all of the illustrations are perfect; for instance, splenic marginal zone lymphoma, a difficult to recognise lymphoma is not very well illustrated, especially the important low power figure, which is not very informative. The references are well chosen, run into 1998, but the number is rather low. The importance of plasmacytosis ("splenitis") is not described. Nevertheless, the value of the book clearly outweighs these remarks and the book is recommended for each practising pathologist who occasionally is confronted with splenic pathology and feels uncomfortable when there is histology that does not look familiar.

A VARGAS

IgA Nephropathy: from Molecules to Man. Tomino Y. (\$99.25.) Karger, 1999. ISBN 3 8055 6833 9.

This book is volume 126 in the "Contributions to nephrology" series. Its stated purposes are to review the author's work on IgA nephropathy and to provide the most up to date findings on the subject. The first of these aims is certainly achieved, but in providing a broad up to date review it is sadly lacking. As

a result of focusing on the author's own work, the text is unbalanced with many important omissions. The reference list is relatively short for a book of this length (274, compared with 711 for the IgA chapter in Heptinstall's *Pathology of the Kidney*) and is out of date in several areas.

The chapters that are potentially of most interest to pathologists are those on histopathology, pathogenesis, and mechanisms of progression. The first of these is a brief eight pages. The introduction to light microscopy (LM) strangely includes a half page summary of a study that reported the absence of DNA polymerase- α positive cells in IgA nephropathy. Hoping that the next section, on LM classification of IgA nephropathy, would make sense of what is currently a confused area, I was disappointed to find that only three systems were discussed, all from Japan (Shirai's, Sakaguchi's, and Sakai's), with no attempt to rationalise disparate schema or to differentiate disease activity from chronicity. The chapters on pathogenesis improve on this poor start, but again are erratic; in some areas, such as alterations in glomerular matrix, it tabulates large amounts of raw data, while omitting other important pieces of recent work. As a result, it is unlikely to satisfy researchers in this field.

Although nephrologists might find some useful information in this book, pathologists will find it of limited value.

I ROBERTS

The Principles of Clinical Cytogenetics.

Gersen SL, Keagle MB, eds. (\$79.50.) Humana Press, 1999. ISBN 0 89603 533 0.

This book is introduced as being "suitable for cytogenetic technologists and clinicians alike", and at first glance, appears to provide a comprehensive overview of all aspects of clinical cytogenetics. However, on closer examination, the book is a rather curious mixture of information. The introductory chapters are perhaps the most confusing. The overview of the biochemistry of genetics is brief, to the point that one needs an intimate knowledge of the processes of replication, transcription, and translation to understand the chapter, thereby rendering it largely surplus to requirements. The chapter on chromosome nomenclature is a rather poor truncation of the Paris ISCN¹ and because the authors are only too happy to refer the reader to suitable manuals for laboratory methodology, it would seem appropriate to do so for this topic also. There is a general lack of cohesion about the book, almost as though none of the authors had any knowledge of the contents of the other chapters. That said, several of the chapters on clinical cytogenetics provided very good overviews, and several included comprehensive tables of data pooled from various sources to give an easily manageable reference for aetiologies of several classes of chromosome disorder. The chapter on cancer genetics, although thorough in its presentation of tumour specific breakpoints, fails to expand on the specific biochemical and genetic results of the rearrangements specified. I felt that this was particularly remiss in the present climate of molecular genetic discovery, because only a few well selected and well described examples would be necessary to whet the reader's appetite for further discovery. The reader should also be aware that the book suffers from shoddy proofreading. Diagrams are

mislabelled, and typographical errors are frequent and often misleading—in the chapter on chromosome nomenclature several examples are given using a chromosome band that does not exist. Overall, I found the book to be a useful aide memoire for several topics, and although perhaps an expensive luxury for the individual, I would recommend the book as an addition to any laboratory or hospital library.

B HOLLAND

1 Mitelman F, ed. ISCN 1995. *An international system for human cytogenetic nomenclature*. Basel: Karger, 1995.

Rotaviruses, Methods and Protocols. Methods in Molecular Medicine. Gray J, Desselberger U, eds. (US\$89.50.) Humana Press, 1999. ISBN 0-896-03736-3.

In the UK between January 1989 and December 1999 there were 164 279 reports to the PHLS Communicable Disease Surveillance Centre of cases of gastroenteritis caused by rotaviruses—an average of 14 934 each year. Rotaviruses were discovered in animals in the early 1960s and in humans in the early 1970s. For several years, electron microscopy was the only widely available method used for diagnosing infection. Since the early 1980s, molecular, serological, and cell culture methods have come into use and fruitful research on these important pathogens has resulted. This excellent new book provides detailed protocols for these methods.

The central chapters begin with an up to date review of the relevant field, all of which are clearly written, informative, and excellently referenced. The editors have provided a short, but informative, introductory chapter aptly titled "Basic facts". In a chapter contributed by BV Venkataram Prasad and Mary Estes, on electron cryomicroscopy and computer image processing techniques, the structure-function studies of rotaviruses are beautifully illustrated with computer generated three dimensional reconstructions of rotavirus particles. A chapter by Mary Ramsay and David Brown describes the epidemiology of rotavirus infections and concentrates on surveillance and the, surprisingly high, disease burden caused by rotaviruses. The other chapters, all of which are of the same high standard, include rotavirus replication, cell entry, genetics, immunology, animal models, serotyping, and genotyping.

G BEARDS

CD-ROM review

Stomatology-ENT. Brocheriou C, Baglin AC, Wassef M, et al. (\$149.00.) Springer-Verlag, 1998. ISBN 3 540 14654 7

This CD ROM of stomatology-ENT is a reference image database of the field of ENT. It is in English and in French. It contains macroscopical and histopathological pictures of the main lesions in the field of oral pathology and ear, nose, and throat pathology. Clinical, radiological, cytological, immunohistochemical, or ultrastructural pictures of some of these lesions are present. Indeed, this CD ROM contains a large

number of pictures of most lesions in this area. The images of interest are very easy to find using a list or keyword driven search. The quality of the photographs is variable; most of them are sharp, but others are not always focused or are very dark. The data sheet contains all relevant information about the picture but this information is often scanty. However, additional information about different lesions is supplied by separate text slides.

There are three fields containing a selection, image, and database window. It is a nuisance that the database window stays on the screen when another program (such as Word or PowerPoint) is used. The program is easy to use and it is very easy to copy the pictures to PowerPoint slides for use in presentations. In addition, they can be copied to a photo editor (such as Photoshop) so that the pictures can be edited.

In conclusion, this CD ROM contains a wealth of photographic material, which can be used for diagnostic or educational purposes. The layout, however, could be improved.

J A KUMMER

Calendar of events

Full details of events to be included should be sent to Maggie Butler, Technical Editor JCP, The Cedars, 36 Queen Street, Castle Hedingham, Essex CO9 3HA, UK; email: maggiebutler@pilotree.prestel.co.uk

BSCC Northern Spring Tutorial: Gynaecological Cytology

8 March 2001, Manchester, UK
Further details: BSCC Office, PO Box 352, Uxbridge UB10 9TX, UK. (Tel +44 01895 274 020; fax +44 01895 274 080; email lesley.couch@psilink.co.uk)

Urological Surgical Pathology for the Practising Pathologist

24–26 March 2001, Sanibel Harbour Resort and Spa, Fort Myers, Florida, USA
Further details: Department of Continuing Education, Harvard Medical school, 25 Shattuck Street, Boston, MA 02115, USA. (Tel +1 617 432 1525; fax +1 617 432 1562; email hms-cme@hms.harvard.edu)

Haematology Morphology 26–27 March 2001, St Mary's Hospital, London, UK

Further details: The Academic Secretary, Department of Haematology, St Mary's Hospital Campus of ICSM, Norfolk Place, London W2 1PG, UK. (Fax +44 020 7262 5418)

Histopathology of the Bone Marrow

28 March 2001, St Mary's Hospital, London, UK
Further details: The Academic Secretary, Department of Haematology, St Mary's Hospital Campus of ICSM, Norfolk Place, London W2 1PG, UK. (Fax +44 020 7262 5418)

Haematological Morphology and Leukaemia Classification for Cytogeneticists

29 March 2001, St Mary's Hospital, London, UK
Further details: The Academic Secretary, Department of Haematology, St Mary's Hospital Campus of ICSM, Norfolk Place, London W2 1PG, UK. (Fax +44 020 7262 5418)

6th European Forum on Quality Improvement in Health Care

29–31 March 2001, Bologna, Italy
Further details: BMA/BJM Conference Unit, BMA House, Tavistock Square, London WC1H 9JR, UK. (Tel +44 020 7383 6409; fax +44 020 7383 6869; email Quality@bma.org.uk; website www.quality-bmj.com)

Diagnostic Histopathology of Breast Disease

23–27 April 2001, Hammersmith Hospital (Imperial School of Medicine), London, UK
Further details: Wolfson Conference Centre, Hammersmith Hospital, Du Cane Road, London W12 ONN, UK. (Tel +44 020 8383 3117/3227/3245; fax +44 020 8383 2428; email wcc@ic.ac.uk)

Gynecologic and Obstetric Pathology

26–29 April 2001, Fairmont Copley Plaza, Boston, Massachusetts, USA
Further details: Department of Continuing Education, Harvard Medical School, 25 Shattuck Street, Boston, MA 02115, USA. (Tel +1 617 432 1525; fax +1 617 432 1562; email hms-cme@hms.harvard.edu)

BSCC London Spring Tutorial: Lung and Pleural Cavity Fluid Cytology 27 April 2001, Guy's Hospital, London, UK

Further details: BSCC Office, PO Box 352, Uxbridge UB10 9TX, UK. (Tel +44 01895 274 020; fax +44 01895 274 080; email lesley.couch@psilink.co.uk)

International Consultation on the Diagnosis of Noninvasive Urothelial Neoplasms

11–12 May 2001, University of Ancona School of Medicine, Torrette, Ancona, Italy
Further details: R Montironi, Ancona Italy (email r.montironi@popcsi.unian.it), DG Bostwick, Richmond, VA, USA (email bostwick@bostwicklaboratories.com), P-F Bassi, Padua, Italy (email bassipf@ux1.unipd.it), M Droller, New York, USA (email michael_droller@smtplink.mssm.edu), or D Waters, Seattle, WA, USA (email waters@vet.vet.purdue.edu)

BSCC Annual Scientific Meeting

9–11 September 2001, Majestic Hotel, Harrogate, UK
Further details: BSCC Office, PO Box 352, Uxbridge UB10 9TX, UK. (Tel +44 01895 274020; fax +44 01895 274080; email lesley.couch@psilink.co.uk)