

Predominant fatty variant of myofibroblastoma of breast

J Baxendine-Jones, J M Theaker, L J Baldwin

Abstract

Myofibroblastoma of the breast is an uncommon but well defined benign stromal tumour. This report describes a case in which the predominant histological component was mature adipose tissue and two further cases with a major adipocytic component. Although small foci of adipose tissue are a recognised feature of this tumour, the dominance of the histological pattern by fat has not been described previously, and the recognition of this variant is important to allow confident diagnosis and avoid confusion with other primary adipocytic or stromal lesions, especially in the setting of potential needle core biopsy of such a lesion.

(*J Clin Pathol* 2001;54:568-569)

Keywords: myofibroblastoma; variant; fatty

We wish to present a myofibroblastoma in which the histological features were dominated by mature adipocytes to such a degree that the diagnosis of myofibroblastoma could only be made after careful assessment and consideration of the diagnosis of an adipocytic lesion, and two further cases with a major adipocytic component, which dominated the histological appearance in some areas.

Case reports

CLINICAL HISTORY

Case 1. A 60 year old woman with a family history of breast carcinoma presented with a 1.5 cm firm, non-tender, mobile mass in the right axillary tail. Mammography demonstrated a relatively well circumscribed density in the right axillary region. Aspiration cytology was unsatisfactory and therefore the mass was excised.

Case 2. A 51 year old woman presented with a small hard lump in the superomedial part of the right breast. An ultrasound scan of the breast showed a 5 mm diameter hypochoic

focus lying in the subcutaneous tissue medial to the breast tissue. Aspiration cytology was unsatisfactory and the mass was excised.

Case 3. A 68 year old woman underwent a mastectomy for invasive ductal carcinoma. The distant random breast tissue examined included an incidental asymptomatic 3 mm well circumscribed nodule.

PATHOLOGICAL FEATURES

The cut surface of the specimens from cases 1 and 2 revealed well defined and circumscribed, firm, grey/white, solid nodules, 20 mm and 12 mm in diameter, respectively. The third case was discovered incidentally on microscopic examination and consisted of a well defined 3 mm nodule. Histologically, the lesions were well delineated from the surrounding breast tissue and composed of irregular nodules and strands of collagenous stroma with intervening fatty stroma (fig 1). The collagenous areas enclosed bland spindle cells with scanty eosinophilic cytoplasm and regular spindle shaped nuclei showing no pleomorphism or mitotic activity (fig 2). Occasional cellular foci with a more epithelioid pattern were present in case 1. No epithelial component was seen in cases 1 or 2 and an occasional small ductule was sited peripherally in case 3. The relative proportion of adipocytic to non-adipocytic elements was approximately 33% in case 2 and approximately 75% in cases 1 and 3. In these last two cases, the relative proportions of fat and cellular stroma varied throughout the lesion, with both cases including areas where the predominant component was fatty.

Immunohistochemistry was performed on cases 1 and 2: a large proportion of the spindle cells in both cases expressed vimentin and desmin (fig 2), with similar expression of α smooth muscle actin in case 1 but only focal expression in case 2. There was no evidence of cytokeratin or S100 protein expression. There was weak focal expression of CD34 in case 1.

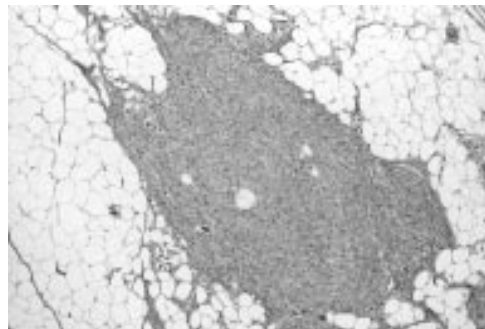


Figure 1 Myofibroblastoma showing good demarcation from the surrounding breast tissue.

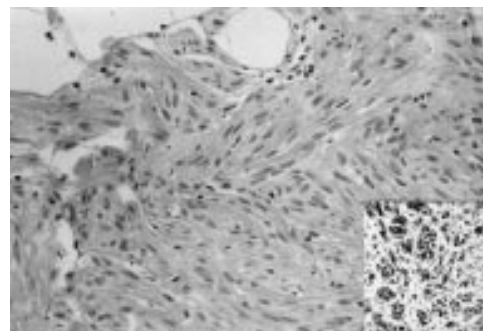


Figure 2 Collagenous stroma containing bland spindle cells with no pleomorphism or mitotic activity. Note the intervening fatty stroma. Inset shows desmin positivity of the spindle cells.

Department of
Histopathology,
Southampton General
Hospital, Tremona
Road, Southampton,
Hampshire,
SO16 6YD, UK
J Baxendine-Jones
J M Theaker
L J Baldwin

Correspondence to:
Dr Theaker
jtheaker@doctors.net.uk

Accepted for publication
20 November 2000

There was insufficient tissue in case 3 to attempt immunohistochemistry.

Discussion

The histological and immunohistochemical features of the spindle cell component of these lesions are those described in myofibroblastoma of the breast.¹ Although generally believed to be true myofibroblastic tumours, it has been suggested that these tumours are mesenchymal tumours capable of diverse lines of differentiation, or are modified myogenic stromal tumours.^{2,3} Several authors have described small lobules of fat scattered throughout these lesions, but only one case had an abundance of fat cells.^{1,3} Magro *et al* have also described a variant of myofibroblastoma that shows atypical spindle cells associated with islands of mature adipocytes.⁴ The major difference between the cases included in this report compared with those described previously is the unusually large adipocytic component. The pronounced fatty component in our cases is potentially misleading and led to serious consideration of the differential diagnosis of spindle cell lipoma. This is also a circumscribed and painless, firm nodule, found more frequently in men, in the regions of the posterior neck and shoulder.⁵ The spindle cells in a spindle cell lipoma are closely associated with a mucoid matrix⁶ and, although immunostaining of the spindle cell in this lesion varies, some are positive for S100 protein.⁶

A needle core biopsy was not attempted in case 1 or 2 because at the time these biopsies were not available routinely in this centre. However, it is now likely that such lesions would undergo core biopsy on presentation, which would provide specimens showing an apparent infiltrative spindle cell process within fatty breast stroma; this could lead to a false diagnosis of fibromatosis or even sarcoma because myofibroblastomas can show mitotic activity and some degree of cellular pleomorphism. Therefore, it is particularly important in this setting to appreciate the wider range of appearances of this benign lesion than hitherto recognised to avoid potential misdiagnosis and inappropriate treatment.

- 1 Wargotz ES, Weiss SW, Norris HJ. Myofibroblastoma of the breast. *Am J Surg Pathol* 1987;11:493–502.
- 2 Schurch W, Seemayer TA, Gabbiani G. The myofibroblast. A quarter century after its discovery. *Am J Surg Pathol* 1998;22:141–7.
- 3 Fukunaga M, Ushigome S. Myofibroblastoma of the breast with diverse differentiation. *Arch Pathol Lab Med* 1997;121:599–603.
- 4 Magro G, Frassetto F, Torrisi A, *et al*. Myofibroblastoma of the breast with haemangiopericytoma-like pattern and pleomorphic lipoma-like areas. *Pathol Res Pract* 1999;195:257–62.
- 5 Bolen JW, Thorning D. Spindle-cell lipoma: a clinical, light- and electron-microscopical study. *Am J Surg Pathol* 1981;5:435–41.
- 6 Enzinger FM, Weiss SW. Benign lipomatous tumours. In: Enzinger FM, Weiss SW, eds. *Soft tissue tumours*, 3rd ed. St Louis: Mosby, 1995:381–430.



Want to extend your search?

Cross journal searching

If you can't find what you are looking for in the *Journal of Clinical Pathology* you can extend your search across many of the more than 200 journals available for selection. You can restrict your search to specific subject areas (eg, clinical medicine, basic research), or select specific journals, or search all available titles.

www.jclinpath.com

Correspondence

Acridine orange stain in the histological identification of *Helicobacter pylori*

The recent paper by Rotimi and colleagues¹ does not mention the acridine orange stain² when comparing staining methods for the identification of *Helicobacter pylori*. The acridine orange stain uses ultraviolet fluorescence in the identification of bacteria. The typical curved morphology of *H pylori* can easily be differentiated from other bacteria.³⁻⁵ I have used this quick, cheap, and reliable stain in routine histopathology reporting for over 16 years and it has proved to be extremely useful in the identification of *H pylori*.

Immunohistochemistry is now recognised as the "gold standard" because it is a highly sensitive and specific staining method.¹ After the publication of the above mentioned article, 20 consecutive gastric biopsies that were positive for *H pylori* using the acridine orange stain were also stained using the polyclonal anti-*H pylori* antibody (Dako, Ely, Cambridgeshire, UK) at a dilution of 1/100. Twenty negative control cases were similarly studied. All 20 cases that were positive with the acridine orange stain were also positive by immunohistochemistry and all negative cases were also negative by immunohistochemistry.

This small study clearly shows that ultraviolet fluorescence of *H pylori* using the acridine orange stain is highly sensitive and compares equally with the gold standard of immunohistochemistry. The acridine orange stain may not be specific, but the morphology of *H pylori* is clearly visible down to the single organism (fig 1).

The only disadvantage of the acridine orange stain is that the microscopic needs a fluorescent attachment, which in my laboratory means turning the lever on a Leitz Diaplan microscope to the required position, without the need for a dark room.

M T HAQQANI

Aintree Hospitals NHS Trust, University Hospital
Aintree, Lower Lane, Liverpool L9 7AL, UK

- 1 Rotimi O, Cairns A, Gray S, et al. Histological identification of *Helicobacter pylori*: comparison of staining methods. *J Clin Pathol* 2000;53:756-9.
- 2 Kronvall G, Myhre E. Differential staining of bacteria using acridine orange buffered at low pH. *Acta Pathol Microbiol Scand [B]* 1977;85:249-54.
- 3 Walters IL, Budin RE, Paull G. Acridine orange stain to identify *Campylobacter pyloridis* in formalin fixed paraffin embedded gastric biopsies. *Lancet* 1986;1:42.
- 4 Haqqani MT, Langdale-Brown B. *Campylobacter pylori* acridine orange stain and ultraviolet fluorescence. *Histopathology* 1988;12:456-7.

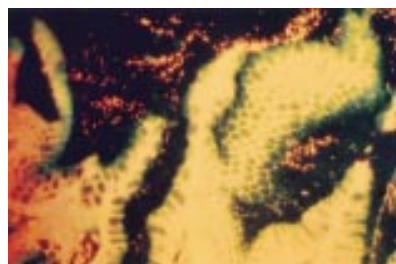

Figure 1 *Helicobacter pylori* stained with acridine orange. Original magnification, $\times 250$.

5 Langdale-Brown B, Haqqani MT. Acridine orange fluorescence, *Campylobacter pylori* and chronic gastritis. *Scand J Gastroenterol* 1990;25:127-33.

The authors reply

In pointing out that we omitted to include acridine orange in our comparison of histological stains for *Helicobacter pylori*, Dr Haqqani seems to have misunderstood the aim of our study. We sought to compare two recently described staining techniques for which there had been claims of superiority over routine methods with our own previously validated routine stain, the modified Giemsa, and with immunohistochemistry using an anti-*H pylori* antibody—the acknowledged histological "gold standard". There was no attempt to be comprehensive and test every possible stain for *H pylori*. Thus, we also omitted from our study the variants of the Gram stain used by some laboratories—the Brown-Hopps,¹ Brown-Brenn,² and the half Gram³—the simple and inexpensive cresyl fast violet⁴ and carbol fuchsin⁵ stains, and the more elaborate Gimenez stain.⁶ The silver impregnation Warthin Starry stain is also used, but is somewhat inconsistent in our hands. Similarly, we have had problems reproducing the silver based Genta "triple" stain.⁷ We have no experience of the more recently described carbol fuchsin-alcian blue-haematoxylin and eosin⁸ and the alcian blue-toluidine blue⁹ methods, which could have been added to the panel. It is evident that stains for *H pylori* have become a cottage industry in which laboratories strive to produce some novel tinctorial mélange, with (in many cases) little thought for sensitivity, specificity, ease of use, reproducibility, and cost.

As is apparent, Dr Haqqani has had a long experience of acridine orange as his preferred routine method. Indeed, by introducing this approach before 1985 he anticipated the need for routine histological assessment of *H pylori* status before many laboratories (including our own), and antedated the first published report of the use of acridine orange for this purpose in 1986.¹⁰ We are happy that he finds acridine orange a good method in his hands. Our early experience led us to conclude that it had no particular advantage over the modified Giemsa. Large numbers of organisms within the mucous layer (as shown in the illustration) are readily seen, but we found that scanty numbers of organisms close to the fluorescent gastric epithelium were difficult to discern.¹¹ We also felt it inappropriate to promote a fluorescent staining method as a routine approach when it requires an ultraviolet light source to be fitted to the microscope, notwithstanding the ease with which Dr Haqqani brings this into action.

However, the claim made by Dr Haqqani that acridine orange is "highly sensitive and compares equally with the gold standard" has to be challenged. To take 20 cases declared positive using the acridine orange stain and then find them all positive with the "gold standard" immunostain offers no validation whatsoever. The most insensitive of stains would pass this test. Likewise, no conclusions can be drawn from re-testing 20 acridine orange negative "control" biopsies. An accurate estimate of sensitivity and specificity can only be obtained by testing large numbers of unselected cases verified as positive or negative by non-histological methods. We would like to re-emphasise that

in an earlier study based on 520 patients who had their *H pylori* status validated by urea breath test, biopsy urease test, and culture, the modified Giemsa had a sensitivity of 98.8% and a specificity of 99.2%.¹² Although this amply justifies our own confidence in the modified Giemsa stain, these results may not be reproduced by different pathologists serving different populations. As stated previously,¹¹ the choice of stain is a matter of personal judgement and laboratory practice. The most valuable requirement is for diligent, enthusiastic histopathologists who can recognise helicobacters by whichever stain they choose.

M DIXON
P MOAYYEDI

Pathology and Centre for Digestive Diseases, General
Infirmary at Leeds, Leeds LS2 9JT, UK

- 1 Westblom TU, Madan E, Kemp J, et al. Improved visualisation of mucus penetration by *Campylobacter pylori* using a Brown-Hopps stain. *J Clin Pathol* 1988;41:232.
- 2 Madan E, Kemp J, Westblom TU, et al. Evaluation of staining methods for identifying *Campylobacter pylori*. *Am J Clin Pathol* 1988;90:450-3.
- 3 Trowell JE, Yoong AKH, Saul KJ, et al. Simple half Gram stain for showing presence of *Campylobacter pyloridis* in sections. *J Clin Pathol* 1987;40:702.
- 4 Burnett RA, Brown IL, Findlay J. Cresyl fast violet staining method for *Campylobacter*-like organisms. *J Clin Pathol* 1987;40:353.
- 5 Rocha GA, Quieroz DM, Mendes EN, et al. Simple carbol fuchsin staining for showing *Campylobacter pylori* and other spiral bacteria in gastric mucosa. *J Clin Pathol* 1989;42:1004-5.
- 6 McMullen L, Walker MM, Bain LA, et al. Histological identification of *Campylobacter* using Gimenez technique in gastric antral mucosa. *J Clin Pathol* 1987;40:464-5.
- 7 Genta RM, Robason GO, Graham DY. Simultaneous visualization of *Helicobacter pylori* and gastric morphology. *Hum Pathol* 1994;25:221-6.
- 8 El-Zimaity HMT, Ota H, Scott S, et al. A new triple stain for *Helicobacter pylori* suitable for the autostainer. *Arch Pathol Lab Med* 1998;122:732-6.
- 9 Carr NJ, Owens EW. A novel alcian yellow-toluidine blue (Leung) stain for *Helicobacter* species: comparison with standard stains, a cost effectiveness analysis, and supplemental studies. *Mod Pathol* 1998;11:72-8.
- 10 Walters LL, Budin RE, Paull G. Acridine-orange to identify *Campylobacter pyloridis* in formalin fixed, paraffin-embedded gastric biopsies. *Lancet* 1986;1:42.
- 11 Dixon MF. Histological diagnosis of *H. pylori*. In: Northfield TC, Mendall M, Goggin, PM, eds. *Helicobacter pylori* infection. London: Kluwer Academic Publishers, 1993:110-15.
- 12 Moayyedi P, Dixon MF. Any role left for invasive tests? *Histology in clinical practice. Gut* 1998;43(suppl 1):S51-5.

Formalin or not formalin; that is the question

We have all faced the dilemma. The laboratory receives a universal container in which a tissue sample is immersed in a clear liquid. The tissue is still pink and blood stained. So has the sample been placed in saline in error or is it in formalin and simply not yet fixed? In time honoured fashion, the laboratory technician or pathologist removes the lid of the container and gingerly inhales. Regrettably, by the time the characteristic odour of formalin is recognised, its noxious and irritant properties have already inflicted their damage upon the teary eyed investigator. It need no longer be this way!

An easily and rapidly applied technique can establish the presence or absence of formalin without placing the investigating staff in harm's way.

Place a few drops of reticulin solution in a beaker and add small drops of your test solution. If the test solution is formalin, the reticulin solution will turn black. A similar effect can be produced by adding the test solution to Schiff's solution. In this case, adding drops of formalin will turn the combination a deep magenta colour. The addition of a test solution of saline (the most frequently encountered alternative) will produce no colour change to Schiff's solution and will turn reticulin solution white. Because all laboratories will have both reagents already prepared on their shelves, the test may be done in a matter of seconds.

Good old fashioned chemistry to the rescue!

D GREHAN
M McDERMOTT
Our Lady's Hospital for Sick Children, Crumlin,
Dublin 12, Ireland

Cytokeratin expression by CD34 positive blasts in a case of refractory anaemia with excess of blasts in transformation (RAEB-t)

Immunohistochemistry has become a very important, and in some cases indispensable, tool in diagnostic pathology, enabling the precise identification of tumours, the detection of micrometastases in a given sample, and the evaluation of various prognosis factors. However, in some cases, the use of multiple but distinct immunostains can lead to some unforeseen results—for example, the expression of an apparently aberrant marker by a neoplasm can sometimes be seen. In this context, we report our experience with a case of refractory anaemia with excess of blasts in transformation (RAEB-t) in which the blasts were unexpectedly found to express cytokeratin (CK).

An 86 year old woman with a past medical history of breast carcinoma treated by mastectomy and adjuvant radiotherapy was admitted to our institution because of worsening anaemia. The following haematological indices were noticed: haemoglobin, 8.6 g/litre; erythrocytes, 2.5×10^{12} /litre; white blood cells, 3×10^9 /litre; and platelets, 465×10^9 /litre. Blasts were also found in peripheral blood (11%). Both bone marrow aspirate and biopsy demonstrated features suggestive of a myelodysplastic syndrome (MDS) (fig 1), identified as an RAEB-t according to the criteria of the French-American-British cooperative group (FAB).¹ Cytochemical study of the blasts revealed the presence of α -naphthyl acetate esterase but not of myeloperoxidase (MPO) or naphthol

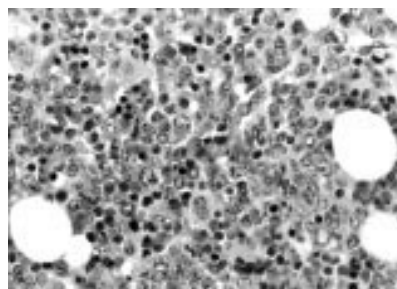


Figure 1 Bone marrow trephine biopsy. The picture shows a hypercellular bone marrow featuring dysplastic megakaryocytes, abnormal erythropoiesis, and increased numbers of blasts. These are often clustered.

ASD chloroacetate esterase. On flow cytometry, the blasts were found to be CD34 positive with expression to some extent of CD13, CD33, CD45, CD45RA, CD117 (c-kit gene product), and CD56. No expression of CD10, CD19, CD45RO or CD90 could be demonstrated. Immunohistochemical studies performed on paraffin wax embedded sections demonstrated CD34 and CD45 positivity in the blasts (fig 2A). However, these cells were MPO, CD3, and CD20 negative. CD68 expression was variable. To exclude with certainty the possibility of an unnoticeable bone marrow infiltration by the underlying breast carcinoma, complementary anti-CK stains using KL-1 and CAM 5.2 antibodies were performed. Surprisingly, the blasts showed a strong perinuclear or punctuate (dot-like) staining pattern (fig 2B). However, these cells did not react with the anti-CK19 antibody, further demonstrating the absence of bone marrow infiltration by the breast carcinoma.

CK expression by myeloid blasts is a very uncommon finding—only three publications (two case reports and one in vitro study) dealing with this matter have been published so far.²⁻⁴ In this setting, the comparison between our findings and those described in these reports allows us to make some interesting comments. First, similar to CK detection reported in various lymphomatous or plasma cell disorders,⁴ the immunohistochemical pattern of CK expression in myeloid blasts is also dot-like or perinuclear. Another similarity between these studies and our case is the use of antibodies that recognise a wide spectrum of CKs (prekeratin, KL-1, AE1/AE3 cocktail, or CAM 5.2).²⁻⁴ Indeed, the KL-1 antibody reacts with the following CK polypeptides: CK1, CK2, CK5, CK6, CK7, CK8, CK11, CK14, CK16, CK17, and CK18. The antibody cocktail AE1/AE3 recognises numerous acidic and basic keratins, namely: CK10, CK14, CK15, CK16, CK19 and CK1, CK2, CK3, CK4, CK5, CK6, CK7, CK8, respectively. Finally, CK8 and CK18 are labelled by the CAM 5.2 antibody. In this regard, it is worth noting that these blasts are stained by

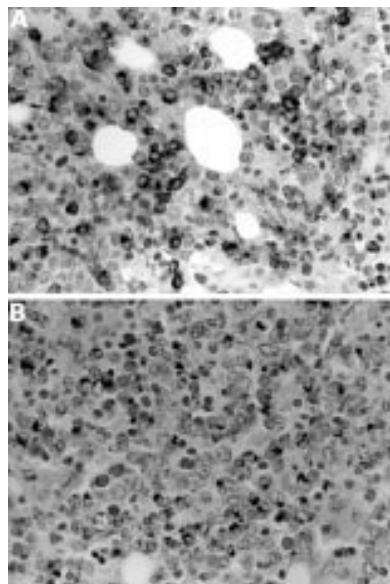


Figure 2 (A) Immunostaining with an antibody directed against CD34 and (B) against CAM5.2. The stained cells look very similar. Note the dot-like staining pattern of CAM 5.2.

AE1 but not by AE3 when these antibodies are used separately.² Another point of interest is the similar differentiation that characterises CK expressing blasts. Indeed, the two reported cases of CK positive acute myeloid leukaemia (AML) reported belonged to the category of AML FAB M4.^{3,4} Although precise subtyping of AML arising from MDS may be difficult, the morphological, cytochemical, and phenotypic features seen in our patient are also consistent with a myelomonocytic differentiation. Like Turner and Milliken,⁴ we found no CK19 expression by the blasts. Therefore, this observation shows that CK19 is a more specific marker of carcinomas showing glandular differentiation than are various pan-CK immunostains.⁵ Whatever the precise explanation for this unusual phenomenon may be, in addition to the two cases published previously, our observation illustrates that CK expression can be seen, albeit rarely, in AML.

The Vesalius Foundation supported this study (thanks to a grant from "La Loterie Nationale").

J-L DARGENT
Department of Pathology, CHU Saint-Pierre/ULB
Institut Jules Bordet, 1 rue Hégier-Bordet, B-1000
Brussels, Belgium
jldargent@hotmail.com

K JOCHMANS
M DE WAELE
Laboratory of Haematology, Academisch
Ziekenhuis-VUB, 101 Laarbeeklaan, B-1090 Brussels

R SCHOTS
Department of Haemato-Oncology, Academisch
Ziekenhuis-VUB

C BOURGAIN
Department of Pathology, Academisch
Ziekenhuis-VUB

- Bennett JM, Catovsky D, Daniel MT, *et al.* The French-American-British (FAB) cooperative group. Proposals for the classification of myelodysplastic syndromes. *Br J Haematol* 1982;51:189-99.
- Zauli D, Gobbi M, Crespi C, *et al.* Vimentin and keratin intermediate filaments expression by K562 leukemic cell line. *Leukemia Res* 1986;10:29-33.
- Ladanyi M, Samaniego F, Reuter VE, *et al.* Cytogenetic and immunohistochemical evidence for the germ cell origin of a subset of acute leukemias associated with mediastinal germ cell tumors. *J Natl Cancer Inst* 1990;82:221-7.
- Turner JJ, Milliken S. A case of keratin-positive acute myeloid leukemia: a possible role for cytokeratin 19 as a specific epithelial marker. *Pathology* 2000;32:98-101.
- Kwaspen FHL, Smedts FMM, Broos A, *et al.* Reproducible and highly sensitive detection of the broad spectrum epithelial marker keratin 19 in routine cancer diagnosis. *Histopathology* 1997;31:503-16.

Audit of colposcopy biopsy sectioning

In April 1999, the guidance document "Histopathology reporting in cervical screening" was issued.¹ On page 45 of that document is the statement "As the appearance of the tissues, even in small biopsies, often shows considerable variation, several levels are required to ensure that small foci of disease are identified". No more specific guidance was given in the document. The issue of what constitutes "several levels" was discussed at the Symposium of Gynaecological Pathology held by the British Division of the International Academy of Pathology in Sheffield on 10 September 1999. It was clear from the discussion that there were many varying practices being used. The practice in




Figure 1 Three slides showing two sections at each of three levels mounted on one slide. The first level is closest to the label. The ink marks have been put on the coverslip by the pathologist to encircle the material for examination at each level and to guide the eye from level to level when examining the material under the microscope (especially useful when the levels are offset on the slide).

the laboratory at the City Hospital Nottingham was to examine two sections at each of three levels of the material, all mounted on to one glass slide. It was decided that this practice should be audited against examining two sections at each of six levels to see whether extra information was gained by this or whether important diagnostic features were being missed by using the existing practice.

The subsequent consecutive 100 colposcopic biopsies were processed according to the standard operating procedure in the laboratory and then two sections 2 µm thick were cut at each of six levels through the material. The levelling was rigorously controlled at 50 µm between each level. The levels were mounted as sections one to three on one slide and sections four to six on a second slide.

The samples were examined microscopically (all by JJ). The slide with levels one to three was examined and the diagnostic features recorded. Only then was the slide with the levels four to six examined. Any variance from the features seen in the first three levels was recorded and commented upon on the record sheet for the audit.

In only seven cases of the 100 examined was further information obtained from the second three levels (levels four to six). In four of these, the comment after examining the first three levels was that levels four to six would have been requested to be cut (always an option) because the diagnosis was not clear on the first three levels and it was felt that further sections might help to clarify the picture. A further three levels would have been requested on six cases; these four were included in the six. In the other two cases no further information was available in the extra three levels. Of the other three cases where additional information was obtained from the second three levels, two showed koilocytes in the squamous epithelium, which were not visible in the first three. This is not a clinically important finding because the management of the women would not have been affected. In the third

case, the second three levels revealed focal stromal inflammation, not visible in the first three levels, also not clinically important.

Relevant histological features are almost always visible on the examination of sections from each of three levels cut from small colposcopic biopsies. In the small number of cases where the diagnosis is not clear on the first three levels, examination of the next three levels (in four of six such cases in our series) may help the pathologist to make the diagnosis. In none of our 100 cases was relevant diagnostic material missed by examining the material at three rather than at six levels. The conclusion reached has been to continue our original practice, thereby preventing the use of extra sectioning time and of twice the number of slides for each case. Critical evaluation of one versus two sections from each level was not conducted but one section would save very little cutting time and six sections sit easily on one slide.

During the course of our study, a letter appeared in the *Journal of Clinical Pathology* stating that sections at levels through the tissue should not be mounted on the same slide because the histological material may not be covered by the coverslip, or might be obscured by mountant.² This was not the case on any of our 200 slides. With careful placing of the material on the slide by the section cutter (fig 1) and an automated coverslipping machine the artefacts mentioned in that letter are not encountered.

J JOHNSON
R HUGHES

Department of Histopathology, Nottingham City Hospital NHS Trust, Hucknall Road, Nottingham NG5 1PB, UK

- 1 Fox H. *Histopathology reporting in cervical screening*. Working party of the Royal College of Pathologists and the NHS Cervical Screening Programme. London: NHSCSP Publication No. 10, April 1999.
- 2 Heatley MK. An assessment of the artefacts introduced by mounting two parallel sections from each histological level of cervical punch biopsies. *J Clin Pathol* 2000;53:85.

Calendar of events

Full details of events to be included should be sent to Maggie Butler, Technical Editor *JCP*, The Cedars, 36 Queen Street, Castle Hedingham, Essex CO9 3HA, UK; email: maggiebutler@pilotree.prestel.co.uk

BSCC Annual Scientific Meeting

9–11 September 2001, Majestic Hotel, Harrogate, UK

Further details: BSCC Office, PO Box 352, Uxbridge UB10 9TX, UK. (Tel +44 01895 274020; fax +44 01895 274080; email lesley.couch@psilink.co.uk)

MicroScience 2002 Exhibitor Launch at ExCel

19 September 2001

Further details: Allison Winton, Exhibition Organiser, Royal Microscopical Society, 37–38 St Clements, Oxford OX4 1AJ, UK. (Tel +44 01865 248768; fax +44 01865 791237; email allison@rms.org.uk or exhibitions@rms.org.uk; website www.rms.org.uk)

Histopathology of the Bone Marrow

3 October 2001, St Mary's Hospital, London, UK

Further details: The Academic Secretary, Department of Haematology, St Mary's Campus of ICSM, Norfolk Place, London W2 1PG, UK. (Fax +44 (0)20 7262 5418)

5th International Course on Bone Marrow Biopsy Pathology

Palermo, 3–6 November 2001

Further details: Vito Franco, Istituto di Anatomia Patologica, Università di Palermo, Italy. (Tel +39 091 6553534; fax +39 091 6553521; email: vfranco@unipa.it; website: www.unipa.it/bmcourse)

Current Concepts in Surgical Pathology

12–16 November 2001, The Four Seasons Hotel, Boston, Massachusetts, USA

Further details: Department of Continuing Education, Harvard Medical School, PO Box 825, Boston, MA 02117-0825. (Tel +1 617 432 1525; Fax +1 617 432 1562; email hms-cme@harvard.edu; web page <http://www.med.harvard.edu/conted/>)

41st St Andrew's Day Festival Symposium on Therapeutics

6–7 December 2001, Royal College of Physicians, Edinburgh, UK

Further details: Eileen Strawn, Symposium Coordinator. (Tel +44 0131 225 7324; fax +44 0131 220 4393; email 2.strawn@rcpe.ac.uk; website www.rcpe.ac.uk)

Correction

Predominant fatty variant of myeloblastoma of breast. Baxendine-Jones J, Theaker JM, Baldwin LJ. *J Clin Pathol* 2001; 54:568–9.

The correct author listing should have been Baxendine-Jones J, Baldwin LJ, Bateman AC, Theaker JM.