

# PostScript

## CORRESPONDENCE

If you have a burning desire to respond to a paper published in *Journal of Clinical Pathology*, why not make use of our "rapid response" option?

Log on to our website ([www.jclinpath.com](http://www.jclinpath.com)), find the paper that interests you, and send your response via email by clicking on the "eLetters" option in the box at the top right hand corner.

Providing it isn't libellous or obscene, it will be posted within seven days. You can retrieve it by clicking on "read eLetters" on our homepage.

The editors will decide as before whether to also publish it in a future paper issue.

### Rare presentation of intestinal amyloidosis with acute intestinal pseudo-obstruction and perforation

Gastrointestinal manifestations of amyloidosis include dysmotility and pseudo-obstruction.<sup>1,2</sup> Here, we report an exceptional case of acute small bowel obstruction followed by perforation in a patient with documented light chain amyloidosis (AL).

A 39 year old Chinese woman had a 10 year history of  $\kappa$  light chain myeloma with associated endstage renal failure requiring dialysis. Her final presentation was precipitated by the acute onset of abdominal pain and vomiting, diagnosed as small bowel obstruction. Laparotomy disclosed jejunal perforation, for which segmental resection was performed. She subsequently died of postoperative complications.

Grossly, the 16 cm long jejunum showed multiple areas of haemorrhagic infarction with one mural perforation site. Histologically, congophilic potassium permanganate resistant green birefringent amyloid was deposited preferentially in vascular channels, particularly in the submucosa, although mesenteric vessels were also involved, and some contained vestiges of organising thrombi. A lesser degree of amyloid deposition was seen within muscularis mucosae and propria, but none was seen in neural plexuses. There was secondary mural acute and chronic ischaemic damage. Ultrastructurally, the amyloid consisted of haphazardly arranged linear non-branching fibrils of 7-15 nm diameter.

The pathological findings were those of AL, preferentially involving vascular channels, with secondary occlusion, and complicating ischaemia with perforation.

This case highlights the clinicopathological differences between the various classes of amyloidosis. Although AL may involve any viscus, the mesenchymal tissues are usually affected.<sup>3</sup>

Gastrointestinal involvement is more common in secondary amyloidosis (AA), especially the mesenteric plexus and vessels,<sup>2</sup> whereas  $\beta$ 2 microglobulin amyloid (AH) is

usually deposited in periarticular sites.<sup>3</sup> Although AH was a consideration in this case because of the history of dialysis,<sup>3</sup> the ultrastructural features of  $\beta$ 2 microglobulin are thick curvilinear fragments of 8-10 nm diameter.<sup>4</sup>

Overall, acute bowel infarction and perforation in amyloidosis are rare, and are usually seen only in cases of systemic disease. More commonly, AL results in chronic intermittent bowel obstruction as a result of gut wall deposition of amyloid.<sup>2</sup> The rare cases of gut perforation related to AA have implicated preferential amyloid vascular deposition. In this unique case, the clinical symptoms of acute bowel obstruction complicated by perforation can be explained by an unusual pattern of amyloid deposition in AL, involving both blood vessels and muscularis. Recognition of this rare possibility may facilitate earlier diagnosis in this disease.

S B Ng, I A Busmanis

Department of Pathology, Singapore General Hospital, Outram Road, 169608 Singapore; [gpthis@sgh.com.sg](mailto:gpthis@sgh.com.sg)

### References

- 1 Gilat T, Spiro HM. Amyloidosis and the gut. *Am J Dig Dis* 1968;13:619-33.
- 2 Tada S, Iida M, Yao T, et al. Intestinal pseudo-obstruction in patients with amyloidosis: clinicopathologic differences between chemical types of amyloid protein. *Gut* 1993;34:1412-17.
- 3 Tan SY, Pepys MB. Amyloidosis. *Histopathology* 1994;25:403-14.
- 4 Gorevic PD, Casey TT, Stone WJ, et al.  $\beta$ 2 Microglobulin is an amyloidogenic protein in man. *J Clin Invest* 1985;76:2425-9.

### Sensitivity to Quorn mycoprotein (*Fusarium venenatum*) in a mould allergic patient

A 27 year old female civil servant presented with five episodes of peri-orbital, tongue, and neck angio-oedema with wheeze and shortness of breath. One of these episodes occurred

a few minutes after eating a Quorn burger. She had a 20 year history of perennial sneezing, rhinorrhoea, and itchy throat, occurring throughout the day and night, but no cough or wheezing. While on holiday in Mauritius she was asymptomatic. Twelve years previously, she had received six months of weekly injections of alternaria, cladosporium, helminthosporium, and stempylum as immunotherapy in France. She had no pets, but had noticed mould on her bedroom and bathroom windows.

Skin prick testing and specific IgE results suggested type 1 hypersensitivities to Quorn, *Alternaria alternata*, *Aureobasidium pullulans*, cat dander, and grass pollen (table 1). Scrapings from her bathroom and bedroom windows grew heavy growths of *Cladosporium sphaerospermum*, *Rhodotorula* sp, *Aureobasidium pullulans*, and fewer numbers of non-sporing mould (Mycology Reference Laboratory, Bristol, UK).

The patient's rhinitis symptoms improved with the regular use of long acting antihistamines, replacing her windows, and controlling humidity at home. She has tried to avoid fungally contaminated food and has had no further episodes of angio-oedema.

Quorn mycoprotein is produced by Marlow Foods Ltd, from the fungus *Fusarium venenatum*.<sup>1,2</sup> Approximately 1/140 000 consumers report adverse reactions after eating Quorn. Ten such complainants had negative skin prick tests to an aqueous extract of fresh Quorn.<sup>3</sup> Thirty three Quorn production workers did not have high titres of IgE specific to Quorn, although six known mould allergic subjects did.<sup>3</sup> This study suggested that the risk of sensitisation to Quorn was low, but that patients who were allergic to mould might react adversely to inhaled or ingested mycoprotein. Crossreactivity studies showed that Quorn shared multiple allergenic determinants with *Aspergillus fumigatus*, *Cladosporium herbarum*, and *Alternaria alternata*.<sup>3</sup> Allergen preparations for skin prick testing and specific IgE tests are poorly standardised, and may differ in their potency as much as

Table 1 Allergy testing results

Allergen	Skin prick testing		Specific IgE	
	Wheal (mm)	Flare	IU/ml	Grade
Grass pollen mix	3	++	ND	ND
Cat dander	4	++	ND	ND
<i>Dermatophagoides pteronyssinus</i>	0	-	ND	ND
<i>Dermatophagoides farinae</i>	0	-	ND	ND
Fresh Quorn mixed with saline	7	++	ND	ND
<i>Alternaria alternata</i>	2	+	4.1	3
<i>Aspergillus fumigatus</i>	1	-	0.4	1
<i>Cladosporium herbarum</i>	1	-	0.6	1
<i>Aureobasidium pullulans</i>	ND	ND	0.8	2

In the skin prick test histamine produced a 6 mm wheal and ++ flare, and saline produced a 0 mm wheal and no flare. Results were those seen 15 minutes after using ALK standardised lancets and skin prick test reagents. The specific IgE tests were performed by Sheffield Protein Reference Unit. When Quorn was used as the allergen a small piece of fresh quorn burger was mixed with saline, and a single drop of liquid from the mixture was put on the patient's forearm as with the other skin prick reagents. No specific IgE was detected to two other fusarium species, *F culmorum* and *F oxysporum*. *Alternaria alternata*, *Aspergillus fumigatus*, and *Cladosporium herbarum* are reported to crossreact with Quorn. There was a heavy growth of *Aureobasidium pullulans* in the patient's home (no tests available to other species isolated). ND, not done.

200–3000 fold.<sup>4</sup> The diversity of fungal allergens is a challenge for successful immunotherapy.

A reduction in occupational exposure to fungi may be achieved using helmets with filtered air (which may remove up to 98% of spores), improving ventilation, and controlling humidity. Fungi in dwellings generally have no specialised spore liberation mechanisms and largely depend on disturbance. Spore wall structure determines whether allergens are already available on the surface, and whether the spores can remain airborne.

**S J Katona, E R Kaminski**

Department of Immunology, Level 7, Derriford Hospital, Plymouth, Devon PL6 8DH, UK; katonas@doctors.org.uk

## References

- 1 **Yoder WT**, Christianson LM. Species-specific primers resolve members of *Fusarium* section *Fusarium*. Taxonomic status of the edible "Quorn" fungus reevaluated. *Fungal Genet Biol* 1998;**23**:68–80.
- 2 **O'Donnell K**, Cigelnik E, Casper HH. Molecular phylogenetic, morphological, and mycotoxin data support reidentification of the Quorn mycoprotein fungus as *Fusarium venenatum*. *Fungal Genet Biol* 1998;**23**:57–67.
- 3 **Tee RD**, Gordon DJ, Welch JA, et al. Investigation of possible adverse allergic reactions to mycoprotein ("Quorn"). *Clin Exp Allergy* 1993;**23**:257–60.
- 4 **Lacey J**. Fungi and Actinomycetes as allergens. In: Kay AB, ed. *Allergy and allergic diseases*. London: Blackwell Science, 1997:858–87.

## Tumour cells produce receptor activator of NF- $\kappa$ B ligand (RANKL) in skeletal metastases

Osteolytic bone destruction is a common complication of tumours that metastasise to bone. Several solid tumours, most notably breast carcinoma, lung carcinoma, and prostate carcinoma, commonly metastasise to bone in patients with advanced disease, where they cause osteolysis and associated pain, hypercalcemia, and fracture. It is generally accepted that osteoclasts are the only cells capable of resorbing mineralised bone. In osteolytic metastases, it has been shown that tumour cells direct osteoclastic bone resorption through a vicious cycle<sup>2</sup>: in particular, tumour cell produced parathyroid hormone related protein (PTH-rP) facilitates bone resorption and, as a consequence, transforming growth factor  $\beta$  is released from the bone matrix and promotes the progression of bone metastases by further inducing PTH-rP production by tumour cells. Other tumour cell products, such as macrophage colony stimulating factor, interleukin 6 (IL-6), IL-11, and tumour necrosis factor  $\alpha$ , have also been reported to be associated with tumour induced osteolysis.

However, with the identification and characterisation of a direct stimulator of osteoclastogenesis—the receptor activator of NF- $\kappa$ B ligand (RANKL,<sup>3,4</sup> also known as ODF, OPGL, and TRANCE)—a possible final common pathway for osteoclastic bone destruction has emerged. A variety of osteotropic factors, such as 1,25-dihydroxyvitamin D<sub>3</sub>, prostaglandin E<sub>2</sub>, parathyroid hormone, IL-6, and IL-11, have been shown to mediate osteoclast differentiation through the upregulation of RANKL expression or the downregulation of osteoprotegerin (OPG; the decoy receptor of RANKL) expression in osteoblast/stromal

**Table 1** A list of tumour bone metastases and RANKL immunoreactivity

Case	Primary site	Diagnosis	RANKL immunoreactivity	
			%	Intensity
1	Breast	Adenocarcinoma	100	Intense
2	Breast	Adenocarcinoma	100	Intense
3	Breast	Adenocarcinoma	95	Intense
4	Breast	Adenocarcinoma	100	Intense
5	Lung	Adenocarcinoma	90	Intense
6	Lung	Adenocarcinoma	95	Intense
7	Lung	Adenocarcinoma	90	Intense
8	Lung	Adenocarcinoma	100	Intense
9	Lung	Adenocarcinoma	100	Intense
10	Lung	Adenocarcinoma	95	Intense
11	Prostate	Adenocarcinoma	90	Intense
12	Prostate	Adenocarcinoma	85	Faint
13	Thyroid	Follicular adenocarcinoma	90	Intense
14	Thyroid	Follicular adenocarcinoma	95	Faint to intense
15	Thyroid	Follicular adenocarcinoma	85	Faint
16	Thyroid	Follicular adenocarcinoma	100	Intense

cells.<sup>5</sup> There is also experimental evidence that tumour produced PTH-rP may stimulate osteoclastic bone resorption by enhancing RANKL expression and reducing OPG expression in the osteoblast.<sup>6</sup> However, whether tumour cells directly produce RANKL, which subsequently mediates osteolysis in metastatic skeletal lesions, has not been determined.

To this end, we have investigated the expression of RANKL in the skeletal lesions of patients with carcinomas that had metastasised to bone. Sixteen cases, including breast carcinoma (four cases), lung carcinoma (six cases), prostate carcinoma (two cases), and follicular thyroid carcinoma (four cases), were collected during surgery of pathological fractures. Histological confirmation of the diagnosis in each case was based on the review of routinely prepared paraffin wax embedded tissue sections in conjunction with knowledge of the clinical and radiological findings. All patients presented with aggressive osteolytic lesions and pathological fracture, and adenocarcinoma was the predominant histological subtype (table 1). The expression of RANKL mRNA and protein was assessed using in situ hybridisation (digoxin labelled RANKL antisense riboprobe, 0.5 ng/ml)<sup>7</sup> and immunohistochemistry (mouse antihuman TRANCE monoclonal antibody from R&D, Minneapolis, Minnesota, USA; StreptABComplex/horseradish peroxidase mouse/rabbit system from Dako, Carpinteria, California, USA), respectively, on paraffin wax embedded tissue sections. Typical histological appearances of neoplastic cells in various bone metastatic tumours were revealed by haematoxylin and eosin staining (fig 1, H&E). The osteoblastic cells of breast carcinoma, lung carcinoma, prostate carcinoma, and thyroid carcinoma showed strong positive hybridisation signals with RANKL riboprobes (fig 1, ISH), and also strong positive staining with anti-RANKL antibodies (fig 1, IHC). RANKL mRNA and protein were also present in osteoblasts and fibroblasts in surrounding tissues (fig 1). Table 1 summarises the percentages of tumour cells exhibiting immunoreactivity for RANKL and the intensity of immunostaining in all 16 specimens. In short, we found that both RANKL mRNA and protein were present in more than 90% and in some cases 100% of metastatic tumour cells in lesions of breast, lung,

prostate, and thyroid adenocarcinoma. Therefore, we conclude that in osteolytic skeletal secondaries, metastatic tumour cells, regardless of origin, express RANKL, and may directly stimulate osteoclastic bone destruction. In support of our observations, Zhang and colleagues<sup>8</sup> have recently provided evidence that tumour cells of prostate cancer are capable of inducing osteoclastogenesis in vitro, directly through the production of soluble RANKL.

Bone resorption is a necessary priming event for the establishment and propagation of tumour metastasis in bone. Our study has been conducted on the metastatic component of the primary carcinoma in the skeleton, and we did not have access to tissues of the primary site. Indeed, there is a paucity of studies that compare RANKL expression in the primary and metastatic tumours of the same patients. Brown and colleagues<sup>9</sup> reported that RANKL was heterogeneously expressed in 10 of 11 prostate carcinoma specimens, and the proportion of tumour cells expressing RANKL was significantly increased in all bone metastases in comparison with non-osseous metastases or the primary prostatic tumour. Whether RANKL expression in the primary tumour is predictive of a possible propensity towards skeletal metastasis remains to be seen and could be the focus of future studies.

## Acknowledgements

This study was fully supported by a grant of the Research Grants Council of the Hong Kong SAR (CUHK/4142/00M).

**L Huang, Y Y Cheng**

Department of Orthopaedics and Traumatology, Chinese University of Hong Kong, Shatin, NT, Hong Kong SAR

**L T C Chow**

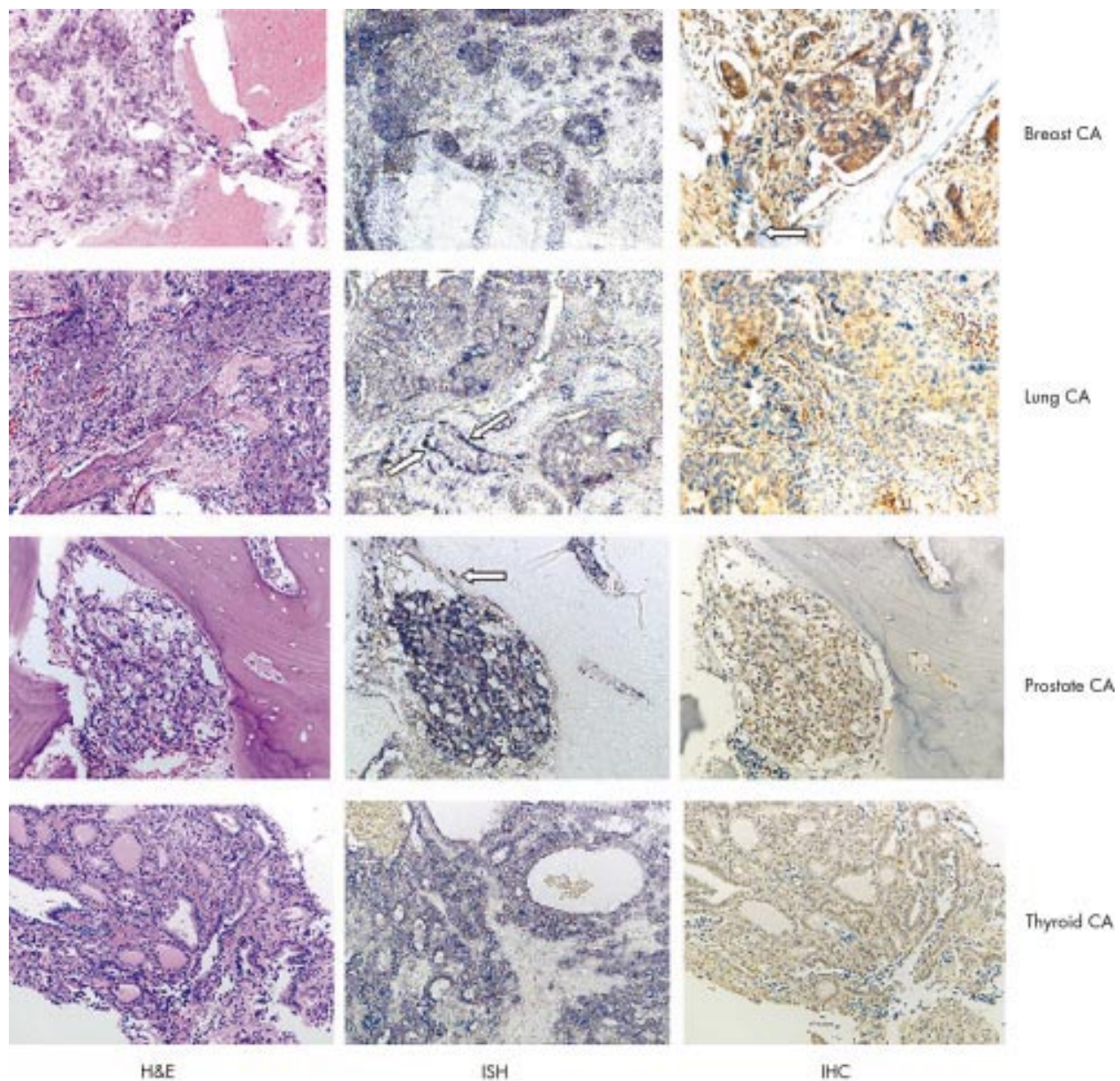
Department of Anatomical and Cellular Pathology, Chinese University of Hong Kong

**M H Zheng**

Department of Orthopaedic Surgery, University of Western Australia

**S M Kumta**

Department of Orthopaedics and Traumatology, Chinese University of Hong Kong; sm-kumta@cuhk.edu.hk



**Figure 1** Expression of RANKL mRNA and protein in bone metastatic tumours. Signals are dark blue in colour. RANKL mRNA was present in the neoplastic cells of various metastatic tumours. Positive signals are brown in colour. RANKL protein was present at different intensities in the cytoplasm of the neoplastic cells of various metastatic tumours. All images are at  $\times 200$  magnification. In addition, when present in surrounding tissues, osteoblasts and fibroblasts also expressed RANKL mRNA and protein (indicated by arrows). H&E, haematoxylin and eosin staining; ISH, in situ hybridisation; IHC, immunohistochemistry.

#### References

- 1 Roodman GD. Biology of osteoclast activation in cancer. *J Clin Oncol* 2001;**19**:3562–71.
- 2 Chirgwin JM, Guise TA. Molecular mechanisms of tumor-bone interactions in osteolytic metastases. *Crit Rev Eukaryot Gene Expr* 2000;**10**:159–78.
- 3 Yasuda H, Shima N, Nakagawa N, *et al*. Osteoclast differentiation factor is a ligand for osteoprotegerin/osteoclastogenesis-inhibitory factor and is identical to TRANCE/RANKL. *Proc Natl Acad Sci U S A* 1998;**95**:3597–602.
- 4 Lacey DL, Timms E, Tan HL, *et al*. Osteoprotegerin ligand is a cytokine that regulates osteoclast differentiation and activation. *Cell* 1998;**93**:165–76.
- 5 Suda T, Takahashi N, Udagawa N, *et al*. Modulation of osteoclast differentiation and function by the new members of the tumor necrosis factor receptor and ligand families. *Endocr Rev* 1999;**20**:345–57.
- 6 Thomas RJ, Guise TA, Yin JJ, *et al*. Breast cancer cells interact with osteoblasts to support osteoclast formation. *Endocrinology* 1999;**140**:4451–8.
- 7 Huang L, Xu J, Wood DJ, *et al*. Gene expression of osteoprotegerin ligand, osteoprotegerin, and receptor activator of NF-kappaB in giant cell tumor of bone: possible involvement in tumor cell-induced osteoclast-like cell formation. *Am J Pathol* 2000;**156**:761–7.
- 8 Zhang J, Dai J, Qi Y, *et al*. Osteoprotegerin inhibits prostate cancer-induced osteoclastogenesis and prevents prostate tumor growth in the bone. *J Clin Invest* 2001;**107**:1235–44.
- 9 Brown JM, Corey E, Lee ZD, *et al*. Osteoprotegerin and rank ligand expression in prostate cancer. *Urology* 2001;**57**:611–16.

#### Are coroners' necropsies necessary? A prospective study examining whether a "view and grant" system of death certification could be introduced into England and Wales

The paper by Ruttly and colleagues<sup>1</sup> fails to focus upon the key issues raised by the question it seeks to answer. Those issues are: (1) What is the "primary purpose" of coroners' necropsies? (2) Is the "information available at the time of necropsy" adequate? (3) What is meant by postmortem examination? Does it only mean dissection of the whole body? (4) Under what circumstances should a necropsy be performed without regard to the views of the next of kin?

In our view, this last issue is the most important and other issues should be dealt with within that context: none of these issues can be dealt with meaningfully without informed public debate. The authors pay lip service only to this question and reach a conclusion "... we consider that necropsies still have an essential role within the coroner's enquiry" that is self evident but superficial.

The paper seems to be based on a false premise—that the "view and grant" facility could replace necropsies. In this study, the causes of death were predicted in 61–74% of cases; in Glasgow, view and grant is performed on approximately 10%<sup>2</sup> of the deaths with which the department of forensic medicine is concerned. This procedure is regarded as an "alternative", an adjunct to detailed review of the circumstances of death, allowing deaths where there is no suspicion or evidence of criminality to be certified without a necropsy.

The authors acknowledge that "the most important" factor in a pathologist's ability to "predict a cause of death before necropsy" is "the quality of the information available to the pathologist". However, there is no assessment of the quality of information provided in this study, despite a publication by one of the authors<sup>3</sup> indicating the relatively poor quality of such information. A key question raised is: "Was there, in fact, no clinical information available or was the absence of information a reflection of inadequate enquiry on the part of the coroner?". The paper does not deal with that question but, sadly, ignores it with the following dismissive statement: "Any additional information concerning the deceased, which subsequently became available after the necropsy, was not included, because this could have caused bias in the second part of the assessment". This appears to us a sad inversion of the importance of the issues.

The inference may be drawn from the paper that where adequate information was provided, allowing a prediction of cause of death, then "the number of correct predictions made of those where a cause of death had been proffered were as follows: A, 70%; B, 63%; C, 59%". This appears to us to be the "true error rate", reducing itself to 30–41%, as opposed to the authors' preferred 54–61%; we would maintain that one should not include in any determination of "error rate" those cases where a prediction could not be made because of inadequate information: under the view and grant system a necropsy would have been carried out in such cases.

In a paper that attaches so much importance to accuracy of cause of death, it is doubly distressing to find a lack of precision in attributing death to "ischaemic heart disease" without further detail of the pathological basis for ischaemia and in finding "bronchopneumonia" an adequate explanation of death.

We think it unfortunate that this paper does not distinguish between the populations of "natural death" and "unnatural death" or give an indication as to whether any of those deaths that were considered to be natural before necropsy were shown to be

unnatural—it is this distinction that appears to us to be the primary purpose of a system of investigation of death in which the wishes of the next of kin are irrelevant.

We welcome the opportunity afforded by the authors to add to the debate regarding the role and future of the coroner system. The authors' implicit support for more detailed investigation of the circumstances of death before postmortem examination sits well with the "radical option"—foreshadowing a "medical examiner" system—detailed in the Home Office consultation document produced in the first phase of its Review of Death Certification, and with recommendation 11—"the feasibility of establishing a new system of death certification involving a medical examiner should be explored"—in recent advice from the chief medical officer.<sup>4</sup>

#### S Leadbeater, D James, A Davison

Wales Institute of Forensic Medicine, B1 Link Corridor, University Hospital of Wales, Heath Park, Cardiff CF14 4XN, UK; leadbeater@cf.ac.uk

#### References

- 1 **Rutty GN**, Duerden RM, Carter N, *et al*. Are coroners' necropsies necessary? A prospective study examining whether a "view and grant" system of death certification could be introduced into England and Wales. *J Clin Pathol* 2001;**54**:279–84.
- 2 **Davison AM**, McFarlane JH, Clark JC. Differences in forensic pathology practice between Scotland and England. *Med Sci Law* 1998;**38**:283–8.
- 3 **Sampson H**, Carter N, Rutty GN. Information before the coronial autopsy: how much should be available? *J Clin Pathol* 1999;**52**:581–7.
- 4 **The removal**, retention and use of human organs and tissue from post-mortem examination—advice from the chief medical officer. London: Her Majesty's Stationery Office, 2001.

### Androgen receptor expression in ductal carcinoma in situ of the breast: relation to oestrogen and progesterone receptors

We wish to add a reference to the list included in the paper of Selim and colleagues<sup>1</sup> concerning androgen receptors in ductal carcinoma in situ (DCIS) of the breast that appeared in the *Journal of Clinical Pathology* in the first issue of 2002. Although the authors state<sup>1</sup> that androgen receptors in DCIS have not been reported previously, we had studied this and published a paper<sup>2</sup> dealing with our observations, in addition to CAG repeat lengths in the androgen receptor in DCIS.

#### M Kasami

Shizuoka Cancer Center Hospital, Naga-Izumi, 411–8777, Japan

#### D L Page

Department of Pathology, Rm-C-3309, MCN, Vanderbilt University Medical Center, 1161 21st Av. So., Nashville, TN 37232–2561, USA; david.page@mcm.vanderbilt.edu

#### References

- 1 **Selim AG**, El-Ayat G, Wells CA. Androgen receptor expression in ductal carcinoma in situ of the breast: relation to oestrogen and progesterone receptors. *J Clin Pathol* 2002;**55**:14–16.
- 2 **Kasami M**, Gobbi H, Dupont WD, *et al*. Androgen receptor CAG repeat lengths in ductal carcinoma in situ of breast, longest in the apocrine variety. *The Breast* 2000;**9**:23–7.

#### Authors' reply

Thank you for this information and the opportunity to reply. Unfortunately, the study of androgen receptor (AR) CAG repeats by Kasami and colleagues<sup>1</sup> is not included in the usual searches and this appears to be the reason for overlooking this reference. In this study, cases of fibroadenoma, ductal carcinoma in situ (DCIS), and invasive mammary carcinoma were included. Twenty four cases of DCIS were tested for AR CAG repeats and 10 were tested for AR expression immunohistochemically. Two of 10 cases were positive for AR and these two cases were the only cases with apocrine morphology. However, in our study,<sup>2</sup> we found that 19 of 57 cases of DCIS expressed AR. Thirteen of those 19 cases were of non-apocrine morphology. In addition, of the nine morphologically apocrine cases, three lacked AR expression. It seems to be that AR is expressed in a subset of DCIS even without apocrine morphology, but it is not necessarily true that all morphologically apocrine cases of DCIS will express AR. In Kasami and colleague's study, none of the cases of invasive mammary carcinoma was tested for AR expression, but other studies<sup>3</sup> have found that a subset of invasive breast carcinomas expresses AR. We feel that a study of AR CAG repeats in benign apocrine metaplasia, which is always immunohistochemically positive for AR,<sup>3</sup> together with and without cases of apocrine and/or non-apocrine in situ and invasive breast carcinoma, would be very valuable in highlighting the importance of CAG repeats and apocrine differentiation.

#### A A Selim, G El-Ayat, C A Wells

Department of Histopathology, St Bartholomew's Hospital, St Bartholomew's and the Royal School of Medicine and Dentistry, Queen Mary and Westfield College, University of London, West Smithfield, London EC1A 7BE, UK; aaselim@doctors.net.uk

#### References

- 1 **Kasami M**, Gobbi H, Dupont WD, *et al*. Androgen receptor CAG repeat lengths in ductal carcinoma in situ of breast, longest in the apocrine variety. *The Breast* 2000;**9**:23–7.
- 2 **Selim AG**, El-Ayat G, Wells CA. Androgen receptor expression in ductal carcinoma in situ of the breast: relation to oestrogen and progesterone receptors. *J Clin Pathol* 2002;**55**:14–16.
- 3 **Ellis LM**, Wiltliff L, Bryant MS, *et al*. Correlation of estrogen, progesterone and androgen receptors in breast cancer. *Am J Surg* 1989;**157**:577–81.
- 4 **Isola JJ**. Immunohistochemical demonstration of androgen receptor in breast cancer and its relationship to other prognostic factors. *J Pathol* 1993;**170**:31–5.
- 5 **Selim AA**, Wells CA. Immunohistochemical localisation of androgen receptor in apocrine metaplasia and apocrine adenosis of the breast: relation to oestrogen and progesterone receptors. *J Clin Pathol* 1999;**52**:838–41.