

PostScript

CORRESPONDENCE

If you have a burning desire to respond to a paper published in the *JCP*, why not make use of our "rapid response" option?

Log on to our website (www.jclinpath.com), find the paper that interests you, and send your response via email by clicking on the "eletters" option in the box at the top right hand corner.

Providing it isn't libellous or obscene, it will be posted within seven days. You can retrieve it by clicking on "read eletters" on our homepage.

The editors will decide as before whether to also publish it in a future paper issue.

Adenocarcinoma arising in villous adenoma of the ampulla of Vater with synchronous malignant gastrointestinal stromal tumour of the duodenum: a case report

An association between ampullary adenoma and adenocarcinoma has been reported previously.¹ However, we believe that this is the first report of the synchronous occurrence of adenocarcinoma of the ampulla of Vater and a gastrointestinal stromal tumour (GIST).

A 41 year old woman was admitted to our hospital for the evaluation of jaundice. Her liver function tests were as follows: alanine aminotransferase, 37 U/litre (normal range, 0-31); aspartate aminotransferase, 32 U/litre

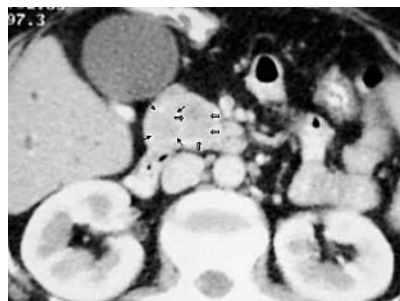


Figure 1 Computed tomography (CT) showed a solid mass, located inferiorly to the pancreatic head and uncinate process. The mass enhanced similarly with pancreatic parenchyma at the early arterial phase. Preoperatively, the mass was interpreted as being located in the pancreatic head. CT images were evaluated retrospectively with the findings at surgery and two different lesions were differentiated (arrows).

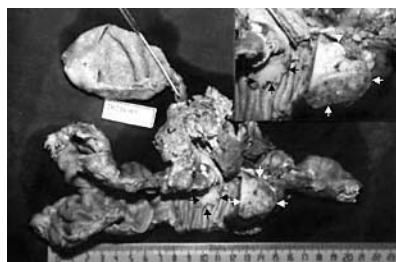


Figure 2 Grossly, a polypoid tumour is located at the duodenal ampulla (black arrows) and another solid subserosal tumour is seen in the second portion of the duodenum (white arrows).

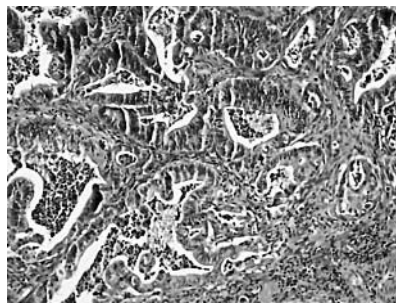


Figure 3 Histological examination of the ampullary tumour revealed moderately differentiated adenocarcinoma; haematoxylin and eosin stain; original magnification, $\times 100$.

(normal range, 0-32); alkaline phosphatase, 598 U/litre (normal range, 0-240); total bilirubin, 203.2 mg/litre (normal range, 1-11); direct bilirubin, 151.6 mg/litre (normal range, 0-3).

Ultrasonography, computed tomography, and magnetic resonance imaging studies showed intrahepatic and extrahepatic bile duct dilatation. Termination of the com-

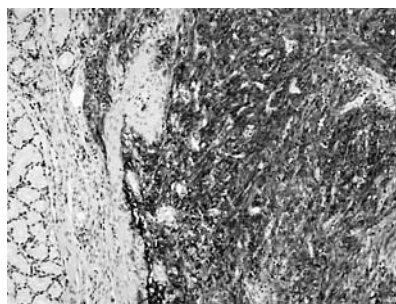


Figure 4 Tumour cells showed a diffuse and strong positive immunoreaction for CD117 in the gastrointestinal stromal tumour; original magnification, $\times 100$.

mon bile duct at the distal end by a mass was noted (fig 1). The initial radiological differential diagnosis included pancreatic head tumour and periampullary carcinoma.

Endoscopic procedures were not performed before surgery. Pancreaticoduodenectomy, cholecystectomy, and distal gastrectomy with lymph node dissection were performed.

Grossly, there was a polypoid tumour ($1.5 \times 1.5 \times 1$ cm) at the duodenal ampulla with a solid subserosal tumour ($3 \times 3 \times 2$ cm) in the second portion of the duodenum (fig 2). On cut section, there was no transition between these two different tumours and no invasion of surrounding tissues and pancreas.

Histologically, the tumours showed a moderately differentiated adenocarcinoma associated with a villous adenoma, which was limited to the ampulla of Vater and a GIST (figs 3 and 4). The GIST was sharply demarcated from the surrounding tissue and it was mainly located at the serosa and muscular layers. Cytologically, the tumour cells had spindle shaped, blunt ended or oval nuclei, with evenly distributed chromatin and moderate pleomorphism; the cells exhibited a fascicular or storiform growth pattern, and had invaded the submucosal layer. Nine atypical mitotic figures for each 10 high power fields (HPF) were present. Immunohistochemically, the tumour cells of the GIST showed diffuse and strong positive immunoreactivity against CD117 (T595; 1/20 dilution; Novocastra, Newcastle, UK), CD34 (QBEND/10; 1/50 dilution, Dako, Glostrup, Denmark).

Stromal tumours involving the small intestine are far less common but seem to have greater malignant potential.² The expression of CD117 has emerged as the most important defining feature and probably the gold standard for diagnosing GISTs.² High mitotic index (more than five mitoses/10 HPF) and larger tumour size (> 5 cm) are generally accepted as the best indicators of malignancy in GIST.² Despite the small size of the tumour, nine atypical mitotic figures/10 HPF, submucosal invasion, and mild pleomorphism of the tumour cells were present in our case.

The possible cause of multiple malignancies include: reduced immunological competence, constitution, genetic factors, chemotherapy, radiation exposure, surgery, or smoking.³ In our patient, a family history of malignancy and other risk factors were not present. It can also be hypothesised that the duodenum was influenced by the same unknown carcinogen, resulting in a simultaneous proliferation of different cell lines (epithelial and stromal cells).⁴

The literature includes case reports of gastric collision tumour composed of GIST intermixed with adenocarcinoma, synchronously occurring GIST and carcinoïd tumour, GIST and lipoma, and GIST and mucosa associated lymphoid tissue lymphoma.^{4,5} To our knowledge, our case is the first

report of the synchronous occurrence of adenocarcinoma of the ampulla of Vater with a GIST.

N H Aksoy

Department of Pathology, Akdeniz University, School of Medicine, 07070 Antalya, Turkey; nazifhikmet@akdeniz.edu.tr

C Çevikal

Department of Radiology, Akdeniz University, School of Medicine

M Ögüş

Department of Surgery, Akdeniz University, School of Medicine

G Ö Elpek, T Gelen

Department of Pathology, Akdeniz University

References

- 1 **Qizilbash AH.** Duodenal and peri-ampullary adenomas. *Curr Top Pathol* 1990;**81**:77–90.
- 2 **de Silva CM, Reid R.** Gastrointestinal stromal tumors (GIST): C-kit mutations, CD117 expression, differential diagnosis and targeted cancer therapy with Imatinib. *Pathol Oncol Res* 2003;**9**:13–19.
- 3 **Nakayama H, Masuda H, Ugaçin W, et al.** Quadruple cancer including bilateral breasts, Vater’s papilla, and urinary bladder: report of a case. *Surg Today* 1999;**29**:276–9.
- 4 **Liu SW, Chen GH, Hsieh PP.** Collision tumor of the stomach: a case report of mixed gastrointestinal stromal tumor and adenocarcinoma. *J Clin Gastroenterol* 2002;**35**:332–4.
- 5 **Al-Brahim N, Radhi J, Gately J.** Synchronous epithelioid stromal tumour and lipoma in the stomach. *Can J Gastroenterol* 2003;**17**:374–5.

Intra-abdominal fibromatosis of the jejunum and mesentery

A 24 year old woman presented with a painless abdominal lump of six months’ duration. She had no history of colonic polyps. A mobile, non-tender, globular mass was felt in the umbilical region. A

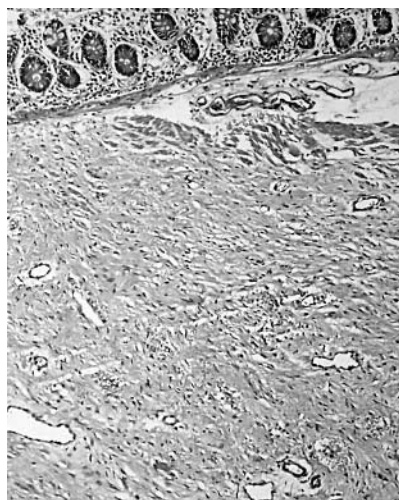

Figure 1 Spindle cell neoplasm infiltrating the muscularis propria of the jejunum.

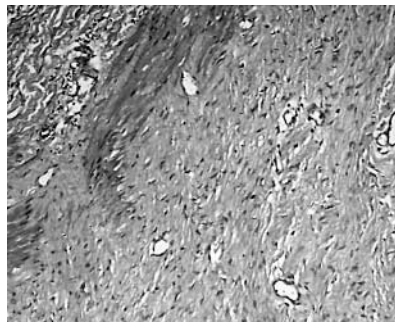


Figure 2 Bland spindle cells and many thin walled vessels forming the neoplasm.

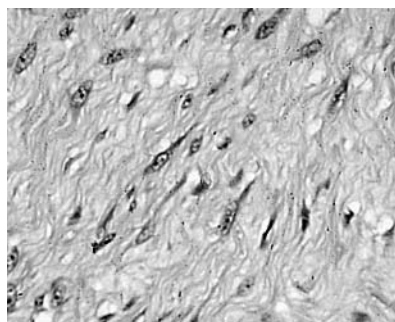


Figure 3 Spindle cells with tapering ends and oval, vesicular nuclei.

computed tomography scan showed a homogenous, non-enhancing mass, possibly arising in the small bowel mesentery.

The tumour was resected entirely with a loop of jejunum. The tumour measured 14 × 12 × 10 cm and was intimately related to the bowel wall. The cut surface was tan, whorled, and firm, without necrosis, cystic change, or haemorrhage. Microscopy showed loosely and haphazardly arranged spindle cells with bland, oval nuclei and minimal cytoplasm (figs 1 and 2). There were also plump spindle cells with tapering ends with oval, vesicular nuclei and moderate amounts of eosinophilic cytoplasm (fig 3).

There were many thin walled vessels of varying calibre (fig 2). There were no cells with epithelioid features, inflammatory cells, calcification, osseous metaplasia, necrosis, or mitoses. The tumour infiltrated the muscularis propria and had infiltrating margins. The tumour cells were negative with antibodies to CD117, S100, CD34, and smooth muscle actin (Dako, St Louis, Missouri, USA; dilutions of 1/200, 1/200, 1/50, and prediluted, respectively) and positive for desmin (Labvision, Fremont, California, USA; 1/200 dilution).

The patient has no evidence of disease 16 months after surgery.

The differential diagnosis of a bland spindle cell tumour involving the gastrointestinal tract and mesentery includes gastrointestinal stromal tumour (GIST), fibromatosis, and inflammatory myofibroblastic tumour.¹ Inflammatory myofibroblastic tumours are more common in children and are characterised by a dense inflammatory cell component among a myofibroblastic proliferation. GIST was considered an unlikely diagnosis because of the whorled

appearance on cut surface; histological evaluation confirmed this. We made a diagnosis of fibromatosis of the jejunum and mesentery.

Intra-abdominal fibromatosis, in its classic presentation, as a mesenteric mass, does not pose a diagnostic problem because of its distinctive gross and microscopic features. However, when it presents primarily as an intestinal wall tumour, the diagnosis of GIST may seriously be considered. Importantly, as many as five of 13 cases of bowel wall fibromatosis in one series had been labelled initially as low grade sarcomas, whereas 13 of 25 in another study mimicked GIST.^{2,3} Distinguishing between the two entities is important because of the different treatment protocols and biological behaviour. GISTs are malignant neoplasms that may be treated by Imatinib mesylate if they are unresectable or if there is a distant metastasis.⁴ They are soft, lobulated, and fleshy on cut surface. Epithelioid cells, skeinoid fibres, mitoses, and necrosis are common.^{1–3} Fibromatosis is a low grade neoplasm that may recur but never metastasises. Recurrence is often related to incomplete excision. Tamoxifen has been used in the management of a recurrent or unresectable tumour.⁵ GISTs usually express CD117 and often CD34 also, whereas fibromatosis is always negative for CD34 and may or may not express CD117.^{1–3} However, fibromatosis is essentially a haematoxylin and eosin diagnosis. The gross appearance—that is, a fibrous mass without necrosis or haemorrhage—gives a clue to the diagnosis.

S A Pai

Department of Pathology, Manipal Hospital, Airport Road, Bangalore 560 017, India; s_pai@vsnl.com

S S Zaveri

Department of Surgical Oncology, Manipal Hospital

References

- 1 **Al-Nafussi A, Wong NACS.** Intra-abdominal spindle cell lesions: a review and practical aids to diagnosis. *Histopathology* 2001;**38**:387–402.
- 2 **Yantiss R, Spiro IJ, Compton CC, et al.** Gastrointestinal stromal tumor versus intra-abdominal fibromatosis of the bowel wall. A clinically important differential diagnosis. *Am J Surg Pathol* 2000;**24**:947–57.
- 3 **Rodrigues JA, Guarda LR, Rosai J.** Mesenteric fibromatosis with involvement of the gastrointestinal tract—A GIST simulator: a study of 25 cases. *Am J Clin Pathol* 2004;**121**:93–8.
- 4 **Connolly EM, Gaffney E, Reynolds JV.** Gastrointestinal stromal tumours. *Br J Surg* 2003;**90**:1178–86.
- 5 **Bauernhofer T, Stoger H, Schmid M, et al.** Sequential treatment of recurrent mesenteric desmoid tumor. *Cancer* 1996;**77**:1061–5.

CORRECTION

Distribution of constitutive (COX-1) and inducible (COX-2) cyclooxygenase in postviral human liver cirrhosis. N A Mohammed, S A El-Aleem, H A El-Hafiz, et al. *J Clin Pathol* 2004;**57**:350–4. The second author’s name should have been S A Abd El-Aleem.

CALENDAR OF EVENTS

Full details of events to be included should be sent to Maggie Butler, Technical Editor JCP, The Cedars, 36 Queen Street, Castle Hedingham, Essex CO9 3HA, UK; email: maggie.butler2@biopenworld.com

Combined Adult and Congenital Cardiovascular Pathology Course

8–10 November 2004, Imperial School of Medicine, National Heart and Lung Institute, London, UK

Further details: Short Course Office, National Heart and Lung Institute, Dovehouse Street, London SW3 6LY, UK. (Tel: +44 (0)20 7351 8172; Fax: +44 (0)20 7351 8246; Email: shourtcourse.NHLI@IC.AC.UK)

Asian Pacific Association for Study of the Liver Biennial Conference

11–15 December 2004, New Delhi, India

Further details: Dr V Malhotra (General Secretary) or Dr P Sakhuja (Treasurer and Pathology Coordinator), Room 325, Academic Block, Department of Pathology, GB Pant Hospital, New Delhi 110002, India. (Tel: +91 11 23237455; Email: welcom@apaslindia2004.com; Website: www.apaslindia2004.com)

BOOK REVIEWS

Zoonoses: infectious diseases transmissible from animals to humans

Edited by H Krauss, A Weber, M Appel, et al. Published by ASM Press, 2003, \$79.95 (paperback). ISBN 1 55581 236 8

We are constantly being bombarded with advice on how to ensure that we lead a healthy life—eat less, drink less, and take more exercise. Reading this book adds to this litany in that we are exhorted not to crack chestnuts with our teeth, to avoid eating ants and, of course, not to apply raw chopped frogs to our wounds if fasciolopsiasis, dicrocoeliasis, and sparganosis, respectively, are to be avoided.

Despite their acknowledged importance, zoonoses are often tucked away at the end

of standard infectious disease textbooks almost as an afterthought, and there have been few texts devoted exclusively to this group of infections. This book, the English language version of the third edition of a book originally published in Germany, is intended to redress the balance. The quality of translation is very good and there are only occasional reminders as to the book's provenance—for example, we are told that the main means of transmission of many zoonotic pathogens is through “smear infection”.

The authors take an essentially organism based approach to the topic, with descriptions of the epidemiology, clinical manifestations, diagnosis, management, and prevention of each infection. Given the sheer number of zoonoses, this means that space that could have been devoted to a more in depth discussion of the major zoonoses is taken up with sections dealing with spectacularly rare conditions, such as lagochilascariasis. Furthermore, several conditions, which have questionable zoonotic origin—such as pneumocystosis—are considered, sometimes at length.

Although the book is crammed with painstakingly collected information, it is still not clear to me how the book is intended to be used. Although the A–Z compendium of common and not so common infections is useful, many potential readers would have appreciated at least one chapter that adopted a more syndromic approach to the patient with unexplained fever. Moreover, a more in depth discussion of the problems in treating zoonoses arising from antimicrobial resistance would have been beneficial. Similarly, clinicians and jobbing diagnostic laboratory workers are unlikely to find page after page of polymerase chain reaction primers for the reverse transcription polymerase chain reaction of oropouche, colti, and other viruses of much value. These are more the province of the research or reference laboratories, which will turn to the primary literature for this information. Those who like textbooks to take a view of the subject in the round might also have appreciated a section dealing with the epidemiology of zoonoses and the profound influence that the climatic, geopolitical, and socioeconomic changes of the last 50 years has had, and will continue to have, on our risks of acquiring these infections.

Nevertheless, this book would be a worthwhile purchase for any departmental library and would be a useful reference for pathologists and clinicians alike. Chopped frog vendors, however, may beg to differ.

K Kerr

Histopathology Specimens: Clinical, Pathological and Laboratory Aspects

Authored by D C Allen, R I Cameron. Published by Springer, 2004, pp 518. ISBN 1 85233 740 0

When reviewing a book of this nature it is difficult to be critical because there are several different methods of specimen handling and processing. The method used is often dependent on personal preference and accepted protocols in individual laboratories. As the authors state in the preface, there is no one correct method; however, irrespective of the method used, maximum information must be obtained from the macroscopic and microscopic examination.

In an era where great importance is placed on the information obtained from macroscopic examination of the specimen and optimal processing of tissue for histological examination, a book to guide pathologists is welcome.

This book covers specimens from 11 anatomical regions, each including numerous specific sites and one miscellaneous section. Each section covers anatomy (including lymphovascular supply, where applicable), clinical presentation, clinical investigations, pathological conditions (both non-neoplastic and neoplastic), clinical aspects of surgical pathology specimens, and laboratory aspects of surgical pathology specimens. The sections on laboratory aspects of surgical pathology specimens provide extensive coverage of specimen types, points to consider in the description of specimens, appropriate selection of blocks, and the essentials of an adequate histopathology report. The last chapter on miscellaneous specimens and ancillary techniques discusses needle core biopsies, fine needle aspirations, cytospin and liquid based cytology, specimen photography, specimen radiography, frozen sections, immunohistochemistry, flow cytometry, in situ hybridisation, electron microscopy, cytogenetics, molecular genetics, and proteomics.

Although there are references to fixatives in specific sections, future editions would benefit by the inclusion of sections on fixatives and optimal fixation, decalcification of specimens, lymph node identifying fluids, and transport media for immunofluorescence biopsies.

The authors intended to provide a book based on their current practice protocols “to educate and better equip all those involved in the histopathology specimen process”, and this they have achieved.

D Govender