

PostScript

CORRESPONDENCE

If you have a burning desire to respond to a paper published in the *Journal of Clinical Pathology*, why not make use of our "rapid response" option?

Log on to our website (www.jclinpath.com), find the paper that interests you, and send your response via email by clicking on the "eletters" option in the box at the top right hand corner.

Providing it isn't libellous or obscene, it will be posted within seven days. You can retrieve it by clicking on "read eletters" on our homepage.

The editors will decide as before whether to also publish it in a future paper issue.

Churg-Strauss vasculitis diagnosed on muscle biopsy

An 81 year old man presented in October 2002 with a three week history of fatigue, generalised myalgia, increasing difficulty in getting up from the sitting position, and "pins and needles" sensation in both hands and feet. His past medical history included late onset asthma at the age of 66, which had gradually become worse over the past year, nasal polyps, and carcinoma of the bladder in 1991, which was removed by cystoscopy. His only medication was inhaled salbutamol as required.

He was unable to stand or walk without support at the time of admission and had generalised muscle wasting. He had grade 3 (Medical Research Council grading) proximal muscle weakness in both lower limbs and grade 4 proximal weakness in both upper limbs. His left handgrip was also weak. His blood pressure was 160/80 mmHg and urine showed a trace of protein and blood, but there were no casts. The rest of the examination was unremarkable.

Investigations revealed haemoglobin of 111 g/litre that was normocytic and normochromic, white blood cell count of 27.8×10^9 /litre with eosinophilia of 15.4×10^9 /litre, platelet count of 611×10^9 /litre, erythrocyte sedimentation rate of 68 mm at one hour by the Westergreen method, C reactive protein of 91 mg/litre, urea of 8.8 mmol/litre, creatinine of 198 μ mol/litre, alanine aminotransferase of 52 units/litre, alkaline phosphatase of 135 units/litre, and creatinine kinase (CK) of 272 units/litre. His eosinophil count gradually rose to 24.8×10^9 /litre and his CK to 538 units/litre over the next few days. Chest radiograph was within normal limits. Renal ultrasound showed evidence of long standing right sided hydronephrosis. Creatinine clearance was reduced at 27 ml/min. Serum antineutrophil cytoplasmic antibodies (ANCA) against myeloperoxidase were positive at 42.1 au/ml, whereas serum ANCA against proteinase 3 were within normal limits. Electromyography (EMG) was normal

and nerve conduction studies showed that the left median motor and sensory amplitude was smaller than on the right.

Renal biopsy was not performed because he had a solitary functioning kidney and there were no active sediments in his urine. We proceeded to open muscle biopsy, despite the normal EMG, in view of his muscle weakness, raised CK, and the need to establish a tissue diagnosis. Frozen sections stained with haematoxylin and eosin showed numerous atrophic fibres scattered throughout the biopsied fascicles, but with no convincing perifascicular distribution. However, the most striking pathological change was that of a florid inflammatory infiltrate in relation to an epimysial medium sized artery (fig 1). The infiltrate was composed of polymorphs predominantly, with smaller numbers of macrophages and lymphocytes. Occasional polymorphs had the granular eosinophilic cytoplasm suggestive of eosinophils. The infiltrate extended through the full thickness of the vessel wall and there was necrosis of the vessel wall with a fibrinoid exudate (fig 2). There was no diffuse eosinophilic infiltration of the tissues and granulomas were not seen. Paraffin wax embedded sections and electron microscopic examination provided no further diagnostic information. The appearances were consistent with an active vasculitis. When considered in conjunction with the clinical picture and investigations, the appearances suggested a diagnosis of Churg-Strauss vasculitis.

The frequency of muscle involvement in systemic vasculitis is poorly defined. Studies looking at the rate of positive muscle biopsies in systemic vasculitis showed that only 13% of biopsies were positive in patients in whom there was a clinical suspicion, whereas 35-37% were positive in patients with confirmed systemic vasculitis.^{1,2} As far as we are aware, there are no published reports of biopsy confirmed Churg-Strauss syndrome associated medium sized vessel vasculitis involving skeletal muscle. Classically, Churg-Strauss syndrome is associated with a medium sized vessel vasculitis, diffuse eosinophilic

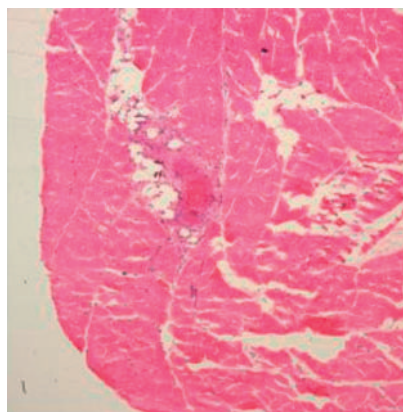


Figure 1 Skeletal muscle biopsy showing an active vasculitis with inflammation extending into surrounding skeletal muscle fascicles (haematoxylin and eosin; original magnification, $\times 2.5$).

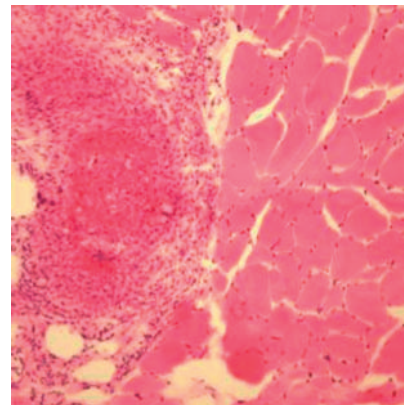


Figure 2 Fibrinoid necrosis of vessel wall. The infiltrate is a mixture of lymphocytes and polymorphs. Note the atrophic skeletal muscle fibres adjacent to the damaged vessel (haematoxylin and eosin; original magnification, $\times 20$).

tic tissue infiltrates, and necrotising granulomas. However, it is rare to find all three histological features in a single biopsy because the lesions tend not to coexist either anatomically or temporally.³

Remission was induced in our patient with a combination of prednisolone, mycophenolate mofetil, and intravenous immunoglobulin.

E Suresh, V B Dhillon

Rheumatic Diseases Unit, Western General Hospital, Crewe Road, Edinburgh EH4 2XU, UK

C Smith, J W Ironside

Neuropathology Unit, Department of Pathology, The University of Edinburgh, Western General Hospital, Crewe Road, Edinburgh EH4 2XU, UK; dr_esuresh@hotmail.com

References

- 1 Maxeiner SR, McDonald JR, Kirklind JW. Muscle biopsy in the diagnosis of periarteritis nodosa. *Surg Clin North Am* 1952;32:1225.
- 2 Wallace SL, Lattes R, Ragan C. Diagnostic significance of the muscle biopsy. *Am J Med* 1958;25:600.
- 3 Hattori N, Ichimura M, Nagamatsu M, et al. Clinicopathological features of Churg-Strauss syndrome-associated neuropathy. *Brain* 1999;122:427-39.

Tumorous amyloidosis of the breast associated with disseminated malignant lymphoma

We report a 77 year old woman with a 14 year history of lymphoplasmacytic lymphoma initially involving the parotid gland, cervical lymph node, and hilar lymph node. She was treated with chlorambucil but the disease ran a protracted course with eventual multiorgan dissemination and required repeated chemotherapy. This time, she presented with bilateral hard, non-tender breast lumps for three months. The clinical diagnosis was lymphoma infiltration versus breast carci-

noma. Mammographic examination showed a 2 cm, medium density, well circumscribed mass in the left breast and a 0.5 cm nodule of similar characteristics with macrocalcifications in the right breast.

Biopsy from the right breast mass showed amyloid deposits with foreign body giant cell reaction. The amyloid was Congo red positive with apple green dichroism under polarised light (fig 1), which persisted after 5% potassium permanganate pretreatment. It also stained positively for amyloid P and negative for AA protein immunohistochemically, confirming AL type amyloid. Ultrastructural examination showed the characteristic non-branching fibrils of indefinite length.

Image guided fine needle aspiration of the left breast mass showed atypical lymphoid cells that had enlarged nuclei and multiple small nucleoli, with mature lymphocytes and histiocytes in the background. Biopsy confirmed lymphoma, with the cells being immunoreactive for CD20 with κ light chain restriction, but not for CD3, CD5, CD10, or CD15, compatible with a diffuse large B cell lymphoma. No lymphoplasmacytic features were identified (fig 2). A small amount of amyloid was seen in the background.

Amyloidosis of the breast was first described in 1973,¹ mostly involving elderly women. The amyloid deposits can either be isolated (amyloid tumour) or associated with plasma cell dyscrasia, connective tissue diseases, carcinoma of the breast, or non-Hodgkin lymphoma.²⁻⁷ Most patients are asymptomatic, although some may present with breast masses, breast tenderness, or peau d'orange. The role of fine needle aspiration cytology in breast amyloidosis is limited because most cases have been diagnosed retrospectively.⁴ Although our patient had a long history (14 years) of lymphoplasmacytic lymphoma, the short duration (three

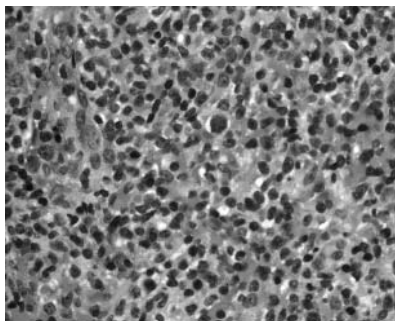


Figure 2 Photomicrograph of the left breast mass showing a diffuse large cell lymphoma (haematoxylin and eosin stain; original magnification, $\times 400$).

months) of the breast masses suggested that the amyloidosis was of recent onset. The absence of serum paraproteins and Bence Jones protein, together with the histological features of the breast lymphoma, indicated progression to a diffuse large cell lymphoma and not a recurrence of the lymphoplasmacytic lymphoma. The mechanism of lymphoma associated amyloidosis has generally been attributed to Waldenstrom's macroglobulinaemia. Our case is unusual because the recent amyloidosis of the breast was not associated with serum paraproteins and the histological picture was compatible with diffuse large cell lymphoma. Because the amyloid in our case is of AL type, low amounts of immunoglobulin, which did not result in serum paraproteinaemia or Bence Jones proteins, may play an important aetiological role. Amyloid has to be considered in the differential diagnosis of breast lumps, particularly in patients with a history of malignant lymphoma. Although the conventional understanding of amyloid formation is related to raised serum paraproteins, as in Waldenstrom's macroglobulinaemia associated with lymphoma, this may not be an absolute prerequisite for tumorous amyloid formation.

P C W Lui

Department of Pathology, United Christian Hospital, Hong Kong

L-M Pang

Departments of Diagnostic Radiology and Organ Imaging, Prince of Wales Hospital, Chinese University of Hong Kong, Hong Kong

T-T Hlaing

Department of Pathology, Kwong Wah Hospital, Kowloon, Hong Kong

G M K Tse

Departments of Anatomical and Cellular Pathology, Prince of Wales Hospital, Chinese University of Hong Kong; garytse@cuhk.edu.hk

References

- 1 **Fernandez BB, Hernandez FJ.** Amyloid tumour of the breast. *Arch Pathol* 1973;**95**:102-5.
- 2 **O'Connor CR, Rubinow A, Cohen AS.** Primary (AL) amyloidosis as a cause of breast masses. *Am J Med* 1984;**77**:981-6.
- 3 **Silverman JF, Dabbs DJ, Norris HT, et al.** Localized primary (AL) amyloid tumour of the breast. *Am J Surg Pathol* 1986;**10**:539-45.
- 4 **Deolekar MV, Larsen J, Morris JA.** Primary amyloid tumour of the breast: a case report. *J Clin Pathol* 2002;**55**:634-5.

- 5 **Sadeghee SA, Moore SW.** Rheumatoid arthritis, bilateral amyloid tumors of the breast, and multiple cutaneous amyloid nodules. *Am J Clin Pathol* 1974;**62**:472-6.
- 6 **Rocken C, Kronsbein H, Sletten K, et al.** Amyloidosis of the breast. *Virchows Arch* 2002;**440**:527-35.
- 7 **Lamovec J, Jancar J.** Primary malignant lymphoma of the breast. Lymphoma of the mucosa-associated lymphoid tissue. *Cancer* 1987;**60**:3033-41.

Lymph node retrieval after neoadjuvant radiotherapy for rectal adenocarcinoma

We read Dr Cserni's review of nodal staging for colorectal cancer with interest.¹ We have recently performed a multivariate analysis of factors affecting lymph node yield after resection of rectal cancer (unpublished data, 2003) and found positive predictors to be tumour size, pT stage, Dukes's stage, number of involved lymph nodes, and examination by a histopathologist with a special interest in gastrointestinal malignancy. These are all mentioned by Dr Cserni in his excellent article. Interestingly, although 29 of our patients underwent neoadjuvant treatment (18 short course radiotherapy; 11 long course chemoradiotherapy) this did not appear to affect lymph node yield, despite previous publications to the contrary.^{2,3} Dr Cserni does not discuss this issue, although an increasing number of patients with rectal cancer are receiving preoperative treatment.

We decided to investigate this further by identifying 15 consecutive cases of rectal cancer resected without neoadjuvant treatment, 13 cases resected after short course radiotherapy (25 Gy in five daily fractions for five days), and 15 patients undergoing chemoradiotherapy before surgery (45 Gy in 25 fractions over five weeks with concomitant 5 fluorouracil based chemotherapy). These were matched for preoperative stage as far as possible (all were T3/T4; N0/N1). Postoperatively, all of the no treatment group were pT3 or pT4 (nine of 15 pN1/2), 11 of 13 short course radiotherapy cases were pT3/4 (five of 13 pN1/2), and 10 of 15 chemoradiated cancers were pT3/4 (six of 15 pN1/2). The total numbers of lymph nodes found in each group were 314, 227, and 226, respectively. The median numbers of nodes found

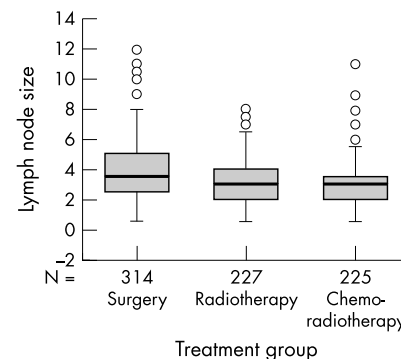


Figure 1 Median diameters of the lymph nodes retrieved from patients treated with surgery only (3.5 mm), short course radiotherapy (3 mm), and long course radiotherapy (3 mm). The numbers of lymph nodes retrieved for each group are shown. The open circles represent outliers.

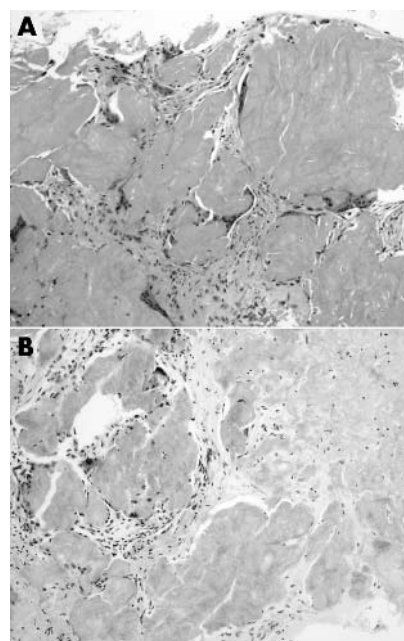


Figure 1 Photomicrograph of the right breast mass showing (A) amyloid deposits with foreign body reaction (haematoxylin and eosin stain; original magnification, $\times 100$) and (B) orange coloured amyloid deposits (Congo red stain; original magnification, $\times 100$).

in each patient in the three groups were 17, 17.5, and 13.5, respectively (not significant; Mann-Whitney U test). The maximum diameter of each node was measured from the histological section on a glass slide with a ruler and expressed to the nearest 0.5 mm. Figure 1 shows the median diameters for each group (surgery only, 3.5 mm; short and long course radiotherapy, 3 mm). Nodes from the short and long course radiotherapy groups were significantly smaller than the surgery only group ($p < 0.001$; Mann-Whitney U test). Nodes from the chemoirradiated group also showed a tendency to be smaller than those harvested after short course radiotherapy ($p = 0.07$). Expressed as percentage of nodes < 5 mm in size, 68.7% of nodes from untreated cancers were < 5 mm in diameter compared with 87% of the short course and long course irradiated groups.

We conclude from this that both short course radiotherapy and chemoradiotherapy given over four to six weeks can significantly reduce the size of mesorectal lymph nodes, presumably as a result of apoptosis and involution. This will make nodes harder to find, but a careful dissection technique by an interested pathologist will still discover substantial numbers.

This is important because as Dr Cserni points out "small lymph nodes (usually defined as ≤ 5 mm) may be the only sites of metastases in colorectal cancer specimens".

N Scott

Department of Histopathology, St James's University Hospital, Leeds LS9 7TF, UK; nigelscott50@hotmail.com

C Thorne, D Jayne

Department of Surgery, St James's University Hospital

References

- 1 **Cserni G.** Nodal staging of colorectal carcinomas and sentinel nodes. *J Clin Pathol* 2003;**56**:327–35.
- 2 **Wichmann MW, Muller C, Meyer G, et al.** Effect of preoperative radiochemotherapy on lymph nodes retrieved after resection of rectal cancer. *Arch Surg* 2002;**137**:206–10.
- 3 **Marijnen CAM, Nagtegaal ID, Krandenburg EK, et al.** No downstaging after short-term preoperative radiotherapy in rectal cancer patients. *J Clin Oncol* 2001;**19**:1976–84.

False glomerulus in renal biopsy specimen: a possible pitfall under the dissecting microscope

Renal biopsy is often invaluable for the diagnosis of glomerular disease. Needle biopsy samples of the renal tissue are usually divided up into separate samples for light microscopy, immunofluorescence, and electron microscopy, preferably under a dissecting microscope.¹ This is a relatively easy task if a sufficient amount of the sample is obtained. However, if biopsy samples are small or turn out to be composed mostly of

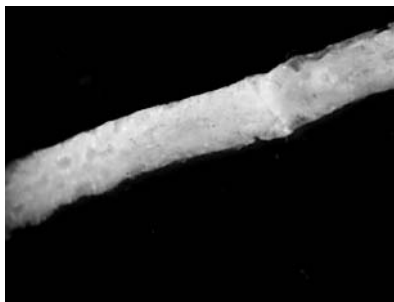

Figure 1 Dissecting photomicrographic features of a renal biopsy sample. True glomeruli are seen at the top right. Several translucent foci simulating glomeruli are seen at the lower left.

medulla, priority is usually given to light microscopy. In such circumstances, one may have to use a part of the sample that does not definitely contain glomeruli. Although one may be lucky enough to find a glomerulus, there are many features that can simulate glomeruli under the dissecting microscope. Unfortunately, there are no instructive publications dealing with the macroscopic features of true or false glomeruli under the dissecting microscope. Here, I will describe the dissecting photomicrographic features of an example of false glomeruli.

Only one sample, about 10 mm in length, was obtained at biopsy. The specimen appeared to contain an inadequate number of glomeruli, so that I selected a focus at the thin edge of the sample with several round translucent spots as a sample for immunofluorescence (fig 1). Stepped sections of the snap frozen tissue were stained with haematoxylin and eosin, but no glomeruli were found. Instead, close aggregates of tubules with a roughly rounded contour were observed. The interstitium showed features of the medulla.

Glomeruli that form small red capillary conglomerates under the dissecting microscope are easily visible, but not all glomeruli within the sample show this feature. Sometimes, most of the glomeruli are anaemic looking. If glomeruli are partially cut, they may be easy to identify because they sometimes protrude above the cut surface. Anaemic glomeruli totally within the sample can sometimes be seen as a relatively well circumscribed and globular translucent area in the sample. Their globular nature can be identified by adjusting the screw of the microscope.¹ A round flat translucent area situated at the thin edge of the sample can be most problematic. Close aggregates of tubules with a roughly rounded contour may, as illustrated in our case, produce a focus simulating glomeruli. The most reliable feature for differentiation should be whether the tissue surrounding the focus is cortex or medulla, which should be discernible from its paler colour, more monotonous texture, and parallel structures.¹

H Hattori

Department of Pathology, Kariya General Hospital, Kariya, Aichi, Sumiyoshicho 5-15 Kariya, Aichi 448-0852, Japan; hattori.kariya-gh.pathol@kariya-gh.or.jp

Reference

- 1 **Nadasdy N, Silva FG.** Nonneoplastic adult renal disease. In: Sternberg SS, eds. *Diagnostic surgical pathology*, 3rd ed. Philadelphia: Lippincott Williams & Wilkins, 1999:1701–84.

CALENDAR OF EVENTS

Full details of events to be included should be sent to Maggie Butler, Technical Editor JCP, The Cedars, 36 Queen Street, Castle Heddingham, Essex CO9 3HA, UK; email: maggie.butler2@bopenworld.com

Surgical Pathology for the Practising Pathologist: Selected Topics

26–29 March 2004, Sanibel Harbour Resort and Spa, Fort Myers, Florida, USA

Further details: Department of Continuing Education, Harvard Medical School, PO Box 825, Boston, MA 02117-0825, USA. (Tel: +1 617 384 8600; Fax: +1 617 384 8686; Email: hms-cme@hms.harvard.edu)

Medicare India

6–8 April 2004, Pragati Maidan, New Delhi, India

Further details: Rob Grant, Kinex Log, 5 New Quebec Street, London W1H 7DD, UK (Tel: +44 (0) 207 723 8020; Fax: +44 (0) 207 723 8060; Email: rob.grant@kinexlog.com; Website: www.medicare-expo.com or www.kinexlog.com)

Diagnostic Histopathology of the Breast

10–14 May 2004, Hammersmith Hospital (Imperial College Faculty of Medicine), London, UK

Further details: Wolfson Conference Centre, Hammersmith Hospital, Du Cane Road, London W12 0NN, UK. (Tel: +44 (0) 20 8383 3117/3227/3245; Fax: +44 (0) 20 8383 2428; Email: wcc@ic.ac.uk)

Practical Pulmonary Pathology

27–30 July, 2004, Brompton Hospital, London, UK

Further details: Professor B Corrin, Brompton Hospital, London SW3 6NP, UK. (Tel: +44 (0)20 7351 8420; Fax: +44 (0)20 7351 8293; Email: b.corrin@ic.ac.uk)

ACP Management Course for Pathologists, 2004

8–10 September 2004, Hardwick Hall Hotel, Sedgfield, County Durham, UK

Further details: V Wood, ACP Central Office, 189 Dyke Road, Hove, East Sussex BN3 1TL, UK. (Tel: +44 (0) 1273 775700; Fax: +44 (0) 1273 773303; Email: valerie@pathologists.org.uk)