

# PostScript

## CORRESPONDENCE

### Authorship trends in the *Indian Journal of Pathology and Microbiology*: going the global way?

Guidelines for authorship of biomedical journals have been available for nearly two decades now to help determine how attribution should be acknowledged.<sup>1</sup> With an increasing number of multiauthored articles and with contributions from diverse specialties, authorship disputes will always raise their head because existing guidelines may not be followed stringently or may be misinterpreted. I analysed author numbers in the *Indian Journal of Pathology and Microbiology* over the past 28 years (1975-2002). The designation of various authors or their individual contributions to the authored papers was not ascertained. In total, 1861 articles comprising 1268 (68.1%) original articles and 593 (31.9%) case reports were studied.

The number of authors for original articles ranged from one to a maximum of 10 (mean, 3.4). The mean number of authors for each article showed a significant increase from 1.9 (SD, 1.4) in 1975 to 3.9 (SD, 1.2) in 2002. The proportion of original articles with single authors declined from 50% in 1975 to none in 2002. Original articles with five or more authors also showed a sharp rise from 5% in 1975 to more than one fourth (26.1%) of all articles in 2002.

The number of authors for 593 published case reports ranged from one to a maximum of eight (mean, 3.5). The mean number of authors for each article showed a significant increase from 2.6 (SD, 1.5) in 1975 to 4.2 (SD, 1.3) in 2002. The proportion of case reports with single authors declined from 40% in 1975 to none in 2002. There were no articles with five or more authors in 1975, whereas 40% of case reports published in 2002 were authored by five or more researchers.

The International Committee of Medical Journal Editors (Vancouver group) drew up the guidelines for authorship based on the principle that each author should be able to defend the work publicly. However, several studies have shown that these guidelines are not followed and the literature abounds with examples of irresponsible authorship.<sup>2-4</sup> Some researchers have recommended doing away with the present designation of author and replacing it with that of a contributor.<sup>5</sup> In India, with many researchers being unfamiliar with the Vancouver guidelines, authorship is, on many occasions, a political decision determined by the position of the author in the hierarchy ladder. Not many junior researchers have the courage to refuse polite implicit or explicit requests from their seniors for inclusion as co-authors, even if their contribution to the work was negligible. The complex factors in the authorship tangle can operate in the reverse direction also, with juniors including senior investigators as co-authors to increase the credibility of the paper and its chances of being accepted. The conferral of gift

authorship also erodes the pillars of ethical attribution. All these practices violate the Vancouver guidelines and cause much anguish to those forced to include non-contributors as co-authors in their work or those who are denied authorship when it is deserved. Authors must accept responsibility for a publication when taking the credit for the same. Institutions also need to address authorship issues head on, and devise ways to deal with such disputes. This vital activity in the biomedical field should not be converted into a power game where only the mighty win.

**N Kakkar**

Department of Pathology, Christian Medical College and Hospital, Ludhiana 141 008, Punjab, India; n\_kakkar@satyam.net.in

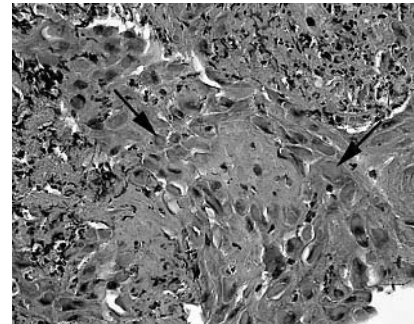
### References

- 1 **International Committee of Medical Journal Editors.** Uniform requirements for manuscripts submitted to biomedical journals. *JAMA* 1993;**269**:2282-6.
- 2 **Bhopal R, Rankin J, McColl E, et al.** The vexed question of authorship: views of researchers in a British medical faculty. *BMJ* 1997;**314**:1009-12.
- 3 **King JT.** How many neurosurgeons does it take to write a research article? Authorship proliferation in neurosurgical research. *Neurosurgery* 2000;**47**:435-40.
- 4 **Shapiro DW, Wenger NS, Shapiro MF.** The contribution of authors to multiauthored biomedical research papers. *JAMA* 1994;**271**:438-42.
- 5 **Rennie D, Yank V, Emanuel L.** When authorship fails. A proposal to make contributors accountable. *JAMA* 1997;**278**:579-85.

### Type A intracytoplasmic inclusions in human cowpox infection

Replication of poxviruses results in the development of intracytoplasmic inclusions that may be visible by light microscopy. Kato *et al* (1959) classified these according to their morphology, staining properties, and rate of accumulation.<sup>1</sup> Type B inclusions are basophilic and occur early in the viral replication cycle. They represent the actual site of viral replication in the cytoplasm and may be seen in all productive poxvirus infections. In contrast, type A inclusions are large, well defined, eosinophilic bodies that develop late in the viral replication cycle. They are composed entirely of a single protein species that has a molecular weight of 160 kDa, but their function is not understood.<sup>2</sup> Type A inclusions are only associated with certain poxvirus infections so that their detection may be diagnostically useful.

We recently reported the clinical presentation of a veterinary surgeon working at a small animal practice who developed a black necrotic ulcer on his finger.<sup>3</sup> Histopathology of a punch biopsy of the lesion unexpectedly revealed epidermal hyperplasia, neutrophil infiltration, and the presence of numerous large eosinophilic intracytoplasmic inclusions, consistent with poxvirus infection (fig 1). Based on this appearance, the differential diagnosis included cowpox (an orthopoxvirus infection), orf, and pseudocowpox (both parapoxvirus infections). In the context of frequent



**Figure 1** Histological examination of a punch biopsy of the skin ulcer stained with haematoxylin and eosin (medium power). Numerous, large, eosinophilic type A intracytoplasmic inclusions are seen (arrows).

occupational exposure to cat scratches but no contact with ungulates, cowpox was the most probable diagnosis. This diagnosis was confirmed by polymerase chain reaction and partial DNA sequencing. Human cowpox is an uncommon and probably underdiagnosed infection that occurs only in Europe.<sup>4</sup> Despite the name, cowpox is rare in cattle. Human infections are probably most frequently acquired from infected cats shedding virus from skin lesions, which gain entry to the human skin through abrasions or scratches.<sup>4, 5</sup>

Laboratory diagnosis of cowpox may be established by electron microscopy of vesicle fluid, by polymerase chain reaction, virus isolation, or serology. However, in our case the histopathological appearances were important in establishing a probable diagnosis of human cowpox before molecular virological confirmation at a reference laboratory. Cowpox virus is recognised as causing large intracytoplasmic inclusion bodies in infected feline tissues and in *in vitro* cell culture.<sup>4</sup> However, such inclusions were not reported among the biopsied cases included in an extensive review of this disease, in which a total of 54 published and unpublished human cases were reviewed.<sup>4</sup> Indeed, an extensive search of the literature found no previous reports of such inclusions being seen in biopsied human cowpox lesions. Histopathologists should be aware that such a histological appearance in an unusual vesicular, pustular, or ulcerated skin lesion obtained from a patient with a history of contact with domestic cats probably results from cowpox infection.

**S D Lawn**

Department of Cellular and Molecular Medicine: Infectious Diseases, St George's Hospital Medical School, London SW17 0RE, UK; stevelawn@yahoo.co.uk

**S Holwill**

Department of Histopathology, St George's Hospital Medical School

### References

- 1 **Kato S, Takahashi M, Kameyama S, et al.** A study of the morphological and cyto-immunological relationship between the inclusions of vaccinia,

- rabbitpox, vaccinia (variola origin) and vaccinia IHD and a consideration of the term "Guarnieri body". *Biken's Journal* 1959;2:343-63.
- Patel DD, Pickup DJ, Joklik WK. Isolation of cowpox virus A-type inclusions and characterization of their major protein component. *Virology* 1986;149:174-89.
  - Lawn SD, Planche T, Riley P, et al. A black necrotic ulcer. *Lancet* 2003;361:1518.
  - Baxby D, Bennett M, Getty B. Human cowpox 1969-93: a review based on 54 cases. *Br J Dermatol* 1994;131:598-607.
  - Willemse A, Egberink HF. Transmission of cowpox virus infection from domestic cat to man. *Lancet* 1985;i:1515.

## Omental actinomycosis presenting with right lower quadrant abdominal pain

A previously healthy 21 year old man presented with a two day history of worsening right lower quadrant abdominal pain. On examination he was found to have a fever (39°C) and his pulse rate was 110 beats/minute. There was tenderness with muscle guarding in the right lower quadrant, which worsened after a period of observation. Basic haematology and biochemistry tests were normal. Plain x rays of the chest and abdomen were also normal.

A diagnosis of acute appendicitis was made and the patient was transferred for emergency appendectomy. The appendix proved to be macroscopically normal but a hard and fairly mobile mass was discovered in the right upper quadrant. We decided to extend the original Lantz incision transversely to improve access. The mass was arising from the right side of the greater omentum. It was loosely adherent to the proximal third of the transverse colon and the overlying peritoneum. The other viscera were normal. The mass was freed and excised with a 1 cm margin of macroscopically unaffected omentum. It was round in shape, 7 cm in diameter, and light brown in colour with an uneven surface.

Histological examination using haematoxylin and eosin staining confirmed that the specimen was a non-caseating granulomatous mass featuring eosinophilic granules. A Gram stained smear prepared from the lesion revealed sulfur granules characteristic of actinomycosis, made up of colonies of Gram positive actinomycetes. Therefore, the mass was an omental actinomycoma.

The patient made an uneventful post-operative recovery. We treated him with intravenous crystalline penicillin, 4MU six hourly for two weeks. Before discharge we investigated the patient's gastrointestinal tract with a barium meal with follow through examination to rule out the possibility of an underlying predisposing condition, such as inflammatory bowel disease or an intraluminal lesion. He was discharged on oral amoxicillin, 500 mg eight hourly for a total of four months. We reviewed him six and then 12 months after surgery. On both occasions his white blood cell count, erythrocyte sedimentation rate, C reactive protein, and computed tomography scan of the abdomen and pelvis were completely normal.

Abdominal actinomycosis is an unusual condition, which tends to be a disease of insidious onset and vague symptoms.<sup>1</sup> Recognised causal associations include a history of appendicitis,<sup>2</sup> diverticulitis,<sup>3</sup> inflammatory bowel disease, intrauterine contraceptive device use,<sup>4</sup> or open and endoscopic surgery. However, we

found no such association in our patient. Pre-operative diagnosis is difficult and requires a high index of suspicion. When actinomycosis is suspected, computed tomography guided aspiration, with or without core biopsy of suspicious lesions, is a useful investigation.<sup>5</sup> This may reduce the number of patients undergoing radical surgery for this benign disease. The role of surgery should be limited to cautious resection of the lesions with delivery of suitable specimens for histology and microbiology.

The organisms tend to be sensitive to cephalosporins, tetracyclines, and macrolides. The duration of treatment is a controversial issue, but long courses are recommended.<sup>1</sup> The prognosis for patients suffering from abdominal actinomycosis is good provided that adequate antibiotic cover is instituted at an early stage.

**J Abela**

Lister Department of Surgery, Glasgow Royal Infirmary, Glasgow G4 0SF, UK; jeabela@hotmail.com

**J Sciberras, M Meilak, A G Felice**

Department of Surgery, St Luke's Hospital MSD09, Malta

**J Degaetano**

Department of Pathology, St Luke's Hospital

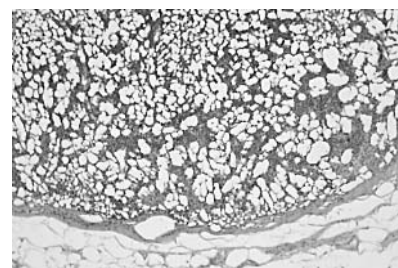
## References

- Shaal KP. Actinomycoses, actinobacillus and related diseases. In: Collier I, Balows A, Sussman M, eds. *Topley and Wilson's microbiology and microbial infections*, Vol. 3, 9th ed. London: Arnold, 1998:777-98.
- Schmidt P, Kolhai JL, Weltzien A. Actinomycosis of the appendix in childhood. *Pediatr Surg Int* 1999;15:63-5.
- Samuel I, Dixon MF, Benson EA. Actinomycosis complicating chronic diverticulitis of the sigmoid colon: a missed association? *Postgrad Med J* 1992;68:57-8.
- Asuncion CM, Cinti DC, Hawkins HB. Abdominal manifestations of actinomycosis in IUD users. *J Clin Gastroenterol* 1984;6:343-8.
- Pombo F, Rodriguez E, Martin R, et al. CT-guided core-needle biopsy in omental pathology. *Acta Radiol* 1997;38:978-81.

## Incidental freezing artefacts in sentinel lymph node biopsies masquerading as lymphangiography artefacts

Sentinel lymph node (SLN) biopsy is a widely used staging procedure. As recently reviewed, possible problems with microscopic interpretation include false positive immunohistochemical staining and benign lesions mimicking metastasis.<sup>1</sup> To my knowledge, no histological artefacts, especially no lymphangiography artefacts, have been attributed to this procedure. I recently encountered an artefact that at first glance seemed to be a lymphangiography artefact.

SLN biopsy is used in our hospital for the staging of breast cancer and was introduced in July 2001. The details of our procedure are as follows. The radioactive tracer is injected intracutaneously or subcutaneously in the affected quadrant of the breast 24 hours before surgery. On the morning of the operation, patent blue dye is injected intracutaneously or subcutaneously in the affected quadrant of the breast. SLN biopsies are fixed in formalin and stored in the operating theatre for 24 hours, after which time, the



**Figure 1** Incidental freezing artefacts in a sentinel lymph node. Lymph node showing empty holes with no reactive changes.

amount of radioactivity is low enough for the specimens to be transported by public highway with no special measures or a licence.

In March 2003, we received two SLN biopsies on the same day, both with artefacts. Throughout the lymph nodes there were empty holes with no reactive changes (fig 1). A similar artefact was noted in the tumour of one of the lumpectomy specimens, making grading of this tumour impossible. All tissues seemed to be adequately fixed in formalin and paraffin wax embedded. No artefacts were noted in other specimens that were processed on the same day. A link was made with the SLN procedure and the artefacts were interpreted as possible lymphangiography artefacts. The departments of surgery and nuclear medicine were contacted to ask whether there had been any changes in the SLN procedure. Both of these departments denied changes to their procedures; specifically, neither of the two tracers was injected in or near the tumour and there was no change in the composition of the tracers. The SLNs taken in 2002 were reviewed and it was noted that the first SLN with the same artefact was taken in the last week of December and the same artefact was also seen in SLNs from January and February 2003. However, the lymph nodes were assessed by different pathologists and the artefacts were not interpreted as related to the SLN procedure.

The department of surgery was again contacted and one of the nurses from the operating theatre mentioned that the SLN biopsies were stored in a refrigerator until transportation. This refrigerator had been switched on after reorganisation of the operating theatre in December 2002, but before that date it had been switched off. On several occasions she had noticed that tissues stored in the refrigerator were frozen and for this reason the refrigerator had been serviced twice, although no improvement was seen. This problem had not been reported to our laboratory and we had never noticed that the SLN specimens were frozen on arrival. We concluded that the artefacts in the SLNs were freezing artefacts and the refrigerator was switched off. Since then the artefact has disappeared.

**P J Westenend**

Pathologisch Laboratorium voor Dordrecht eo, Laan van Londen 1800, Dordrecht, 3317 DA, The Netherlands; pwestenend@paldordt.com

## Reference

- Hoda SA, Chiu A, Resetskova E, et al. Pathological examination of sentinel lymph node in breast cancer: potential problems and possible solutions. *Microsc Res Tech* 2002;59:85-91.

## Can routine laboratory data guide empirical prescribing?

Smellie and colleagues have noted large and significant differences in rates of submission of samples for microbiological testing between practices in the south west and north east regions.<sup>1</sup> They think that these data indicate that some practices are more selective in the use of the laboratory and speculate that routine laboratory generated antibiotic surveillance data will thus tend to include more complicated cases and overestimate antibiotic resistance. The authors therefore question the validity of using routine laboratory data on antibiotic resistance for primary care based therapeutic guidelines for empirical prescribing, and recommend an enhanced surveillance programme with a standardised approach to testing as a better way of informing such guidelines. We have recently completed such a programme for urinary tract infection (UTI) and can therefore comment on these suggestions.

The susceptibility data for uropathogens recovered from routine urine samples received from the 80 practices served by Cambridge Microbiology and Public Health Laboratory were compared with the results from a sentinel group of five practices in the same locality, which agreed to submit urine samples on all patients presenting with a clinical diagnosis of UTI within a three month period during 2002.

In total, 967 urine samples were received from the sentinel practice group and 18 892 from the general practice group. Bacteria were recovered from 269 and 4449 samples from the two groups, respectively. Overall, 89% were Gram negative bacilli and the numbers of these were large enough to permit meaningful comparison and statistical evaluation. There were no significant differences in recovery of any species between the two groups, indicating that, in contrast to the assertion of Smellie *et al.*, any bias by general practitioners to send in samples with complicated infections involving more resistant organisms, such as *Pseudomonas* spp, did not result in overestimating the extent of antibiotic resistance in our population.

Resistance rates to cefalexin, norfloxacin, and gentamicin were marginally lower (2.5% *v* 5.2%, 2.1% *v* 4.4%, and 0.8% *v* 1.3%, respectively) and resistance to ampicillin, trimethoprim, and co-amoxiclav was slightly higher (46.0% *v* 45.1%, 22.8% *v* 19.8%, 18.1% *v* 11.7%, respectively) in the sentinel practice group than in the general practice group. However, only the resistance rate for co-amoxiclav was significantly different (*p* = 0.03 by two tailed  $\chi^2$  test).

Two other studies of enhanced surveillance programmes have been published, also investigating UTI. Baerheim *et al.* reported a study on female patients with UTI in general practice in Norway, comparing resistance rates for bacteria recovered from unselected (sentinel) patients with those from whom urine was sent routinely, using a panel of six antibiotics.<sup>2</sup> Uropathogens from the sentinel group were 3.4–8.4% less resistant to the antibiotics tested, but the results were significant only for nitrofurantoin (3.0% resistant in sentinel patients compared with 9.7% resistant in routine patients).

Richards reported a study similar to our own over a 12 month period involving three sentinel general practices in Norfolk, UK.<sup>3</sup> Sentinel practice resistance rates were the

same, or very slightly higher for co-amoxiclav, ciprofloxacin, cefradine, and gentamicin and slightly lower for ampicillin, cefuroxime, and trimethoprim. The difference was largest with trimethoprim (18% resistant in sentinel practice patients versus 22% resistant in all other practices), and only this difference achieved significance. We did not duplicate their findings; indeed, the pattern for lesser or greater resistance in the sentinel practice group versus all general practice was reversed in our study.

There is no consistency in antibiotics showing greater or lesser resistance rates in sentinel practice patients in these studies. However, a common feature of all three is that the differences in resistance rates for sentinel practices compared with overall reported resistance rates are small, and none would justify a change in recommendations for empirical prescribing for UTI in general practice. We conclude that there is good evidence that susceptibility data derived from routine urine samples received by the laboratory provide reliable information for formulating empirical prescribing guidelines for urinary tract infections in domiciliary practice. We suspect that this also applies to specimens from other sites, but this requires further study.

### H Ludlam

Health Protection Agency, Clinical Microbiology and Public Health Laboratory, Addenbrooke's Hospital, Cambridge CB2 2QW, UK; hugo.ludlam@addenbrookes.nhs.uk

### O Sule

Clinical Microbiology Laboratory, Royal Free Hospital, London NW32Q9, UK

### M Knapton

Cambridge City Primary Care Trust, Heron Court, Ida Darwin, Fulbourn, Cambridgeshire CB1 5EE, UK

### I Abubakar

Communicable Disease Surveillance Centre Eastern, IPH, University Forvie Site, Robinson Way, Cambridge CB2 2SR, UK

## References

- 1 Smellie WSA, Clark G, McNulty CAM. Inequalities of primary care microbiology testing between hospital catchment areas. *J Clin Pathol* 2003;56:933–6.
- 2 Baerheim A, Digranes A, Steinar H. Are resistance patterns in uropathogens published by microbiology laboratories valid for general practice? *APMIS* 1999;107:676–80.
- 3 Richards J. Monitoring antibiotic resistance in urinary isolates from the community—a spotter practice model. *Communicable Disease and Public Health* 2002;5:226–9.

## BOOK REVIEW

### Surgical pathology dissection. An illustrated guide, 2nd ed

Westra WH, Hruban RH, Phelps TH, Isaacson C. (£56.00.) Springer, 2003. ISBN 0 387 95559 3.

Because I am particularly obsessed with standardisation of the grossing of specimens, reviewing a book devoted entirely to this extremely important aspect of surgical pathology was something I did with relish.

As is set out in the foreword, the grossing guidelines contained in the book conform, in

the main, with the recommendations of the College of Pathologists and the Association of Directors of Anatomic and Surgical Pathology, although the contributors are from one institution.

The style of the book is very simple and the reader is “talked” through the dissection. There are line drawings of the specimens and where sections of the specimen should be taken from. Although in black and white, this does not detract from the essence of the book. As such, it is an excellent instruction manual that should form the basis of every cut up manual anywhere in the world. Although there are regional variations and personal quirks, there is only one way to gross a specimen properly and that is the right way. This book will point anyone who is at the cut up bench in the right direction.

I thoroughly recommend this book to all registrars, pathologists, and pathologist's assistants.

R Chetty

## CALENDAR OF EVENTS

Full details of events to be included should be sent to Maggie Butler, Technical Editor JCP, The Cedars, 36 Queen Street, Castle Hedingham, Essex CO9 3HA, UK; email: maggie.butler2@biopenworld.com

### Practical Pulmonary Pathology

27–30 July, 2004, Brompton Hospital, London, UK

Further details: Professor B Corrin, Brompton Hospital, London SW3 6NP, UK. (Tel: +44 (0)20 7351 8420; Fax: +44 (0)20 7351 8293; Email: b.corrin@ic.ac.uk)

### ACP Management Course for Pathologists, 2004

8–10 September 2004, Hardwick Hall Hotel, Sedgfield, County Durham, UK

Further details: V Wood, ACP Central Office, 189 Dyke Road, Hove, East Sussex BN3 1TL, UK. (Tel: +44 (0) 1273 775700; Fax: +44 (0) 1273 773303; Email: valerie@pathologists.org.uk)

### Asian Pacific Association for study of the Liver Biennial Conference

11–15 December 2004, New Delhi, India

Further details: Dr V Malhotra (General Secretary) or Dr P Sakhuja (Treasurer and Pathology Coordinator), Room 325, Academic Block, Department of Pathology, GB Pant Hospital, New Delhi 110002, India. (Tel: +91 11 23237455; Email: welcome@apasindia2004.com; Website: www.apasindia2004.com)

## CORRECTION

**Suspicious urinary cytology with negative evaluation for malignancy in the diagnostic evaluation of haematuria: how to follow up?** G Nabi, D Greene, M O O'Donnell *J Clin Pathol* 2004;57:365–8. The third author's name was incorrectly spelt: it should have been M O O'Donnell. In addition, this author would like it to be known that she did not see the proofs before the paper was published.