

# PostScript

## CORRESPONDENCE

If you have a burning desire to respond to a paper published in the *Journal of Clinical Pathology*, why not make use of our "rapid response" option?

Log on to our website ([www.jclinpath.com](http://www.jclinpath.com)), find the paper that interests you, and send your response via email by clicking on the "eletters" option in the box at the top right hand corner.

Providing it isn't libellous or obscene, it will be posted within seven days. You can retrieve it by clicking on "read eletters" on our homepage.

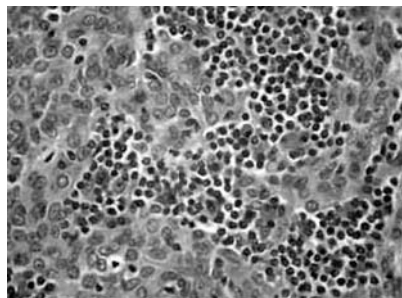
The editors will decide as before whether to also publish it in a future paper issue.

### Lymphadenoma of the salivary gland: a rare tumour

Lymphadenoma of the salivary gland is a very rare (or possibly even under-reported) tumour with only sparse reports found in the literature. It is not mentioned in most textbooks on salivary gland tumours or head and neck pathology.<sup>1–3</sup> The 1996 Armed Forces Institute of Pathology fascicle briefly discusses the entity as a variant of sebaceous lymphadenoma ("lymphadenoma that lacks sebaceous differentiation").<sup>4</sup> We report a case of lymphadenoma arising from the parotid gland.

A 74 year old man presented with a solitary mass in his parotid gland. A computed tomography scan suggested the possibility of pleomorphic adenoma. Fine needle aspiration was subsequently done, raising the possibility of a Warthin's tumour. A superficial parotidectomy was then carried out for a definitive diagnosis, including a small amount of sternocleidomastoid muscle to ensure clearance.

Grossly, the tumour was a well demarcated, solid grey/white mass measuring 1 cm in diameter. Microscopic examination revealed anastomosing islands of epithelial cells within a dense lymphoid stroma (fig 1). A few glandular lumina and cysts containing dense eosinophilic secretions were seen at the periphery of the nodule. No sebaceous glands were identified. There was no evidence of



**Figure 1** Islands of epithelial cells accompanied by a prominent lymphoid stroma.

cytological atypia or abnormal mitotic activity. On immunohistochemistry the anastomosing cells were positive for epithelial and basal cell markers (epithelial membrane antigen, MNF116, 34BE12, and S100). The absence of sinuses and nodal capsule excluded the possibility of the tumour arising from an intraparotid lymph node.

Ma *et al* in 2002 reported three patients with lymphadenoma of the salivary gland, all males, with ages ranging from 13 to 57 years.<sup>5</sup> They noted the difficulty of diagnosing this entity, as a result of the indistinct appearance without sebaceous cells. Therefore, other tumours such as Warthin's tumour, lymphoepithelial cysts, sebaceous lymphadenoma, metastatic carcinoma, and malignant lymphoma also need to be considered.<sup>4,5</sup> Proper recognition of this rare tumour is necessary to avoid confusion in the diagnosis. Our diagnosis in this case was confirmed by Chan, a co-author of the previously mentioned case report. Too few cases have been documented to comment on its behaviour.

**N B Musthaya, S E Low, R H Seneviratne**

Department of Histopathology, Arrowe Park Hospital, Upton, Wirral CH49 5PE, UK; [mustsri@hotmail.com](mailto:mustsri@hotmail.com)

### References

- 1 **Dardick I.** *Colour atlas/textbook of salivary gland tumour pathology.* New York: Igaku-Shoin, 1996.
- 2 **Cawson RA, Binnie WH, Speight PM, et al.** Benign salivary gland tumours and general aspects. In: Cawson RA, Binnie WH, et al, eds. *Lucas's pathology of tumors of the oral tissues*, 5th ed. Hong Kong: Churchill Livingstone, 1999:369–83.
- 3 **Luna MA.** Salivary glands. In: Pilch BZ, ed. *Head and neck pathology.* Philadelphia: Lippincott Williams and Wilkins, 2001:284–349.
- 4 **Ellis GL, Auclair PL.** *Tumours of the salivary glands, atlas of tumour pathology, 3rd Series, Fascicle 17.* Washington DC: Armed Forces Institute of Pathology, 1996:135–6.
- 5 **Ma J, Chan JKC, Chow CW, et al.** Lymphadenoma: a report of three cases of an uncommon salivary gland neoplasm. *Histopathology* 2002;41:342–50.

### Gastric precancerous lesion follow up based on pathological evidence

We read with interest the article by Dinis-Ribeiro *et al* addressing the follow up of "atrophic chronic gastritis and intestinal metaplasia (IM)".<sup>1</sup> The authors conclude that: (1) "in patients with atrophic chronic gastritis or with type I IM, a three yearly follow up could be suitable"; and (2) "patients with type III IM may benefit from 6–12 monthly (follow up)".

How precancerous lesions are histologically assessed and followed up are fields of our interest and we would raise some methodological concerns about the published study.

In assessing atrophy, it would be advisable to adopt the classification(s) proposed by the current international literature. The original Sydney system was recently revised by a group of specialists in gastrointestinal pathology (including the authors of the original classification), prompting important changes in the previous diagnostic criteria.<sup>2,3</sup> The new version was also validated by testing its

interobserver consistency. The adoption of such internationally shared criteria facilitates comparisons between studies.

As for the histological classification of dysplasia, the Dinis-Ribeiro study applied the Vienna criteria, which include category 4.3 (suspicious for invasive carcinoma) among the non-invasive neoplasia categories (NiN). From a biological standpoint at least, this category is quite distinct from the NiN categories. Recently, two classifications have been proposed for gastric NiN arising in the stomach; here again, adopting the World Health Organisation criteria would enable an easier comparison between this and other studies.<sup>4,5</sup>

Finally, the authors report that the two pathologists assessing the slides agreed in 85% of cases; it would have been better to express interobserver consistency properly, in terms of *K* statistics.

To define the "entry biopsy" as "first or intermediate" is a contradiction in terms, which may introduce a bias in the calculation of the follow up time and which influences the validity of the results. The authors state that 144 patients were included in the study and, a few lines later, that 239 pairs of endoscopy biopsies were considered. In view of the fact that they also say that no less than two biopsy samples were taken at each endoscopy, the numbers become bewildering.

In dealing with precancerous lesions, extensive sampling protocols (always including the angular mucosa) are mandatory.<sup>6</sup> To say that "more than 15% of patients had more than four biopsies for each endoscopy" is not satisfactory, either for the patient's safety or for any speculation vis-à-vis the "follow up model"—particularly because the follow up ranged from 3.2 to 36.2 months in 41 of the 144 patients.

An important outcome of the study would be the demonstration that low grade NiN can progress to more severe lesions (invasive or non-invasive?), but the clinical value of this observation is considerably reduced by the short follow up and the difficulty in correlating the number of biopsy samples (239) with the number of patients (144).

On the whole, we found the message emerging from the Dinis-Ribeiro study a valuable contribution to our understanding of the natural history of gastric carcinogenesis. Our critical comments are intended simply as a reminder that caution is needed in recommending follow up protocols unless all the essential conditions can be met to support such recommendations.

**M Cassaro, G Pennelli, M Rugge**

Department of Surgical and Oncological Sciences, University of Padova, Via A. Gabelli 61, I-35121 Padova, Italy; [massimo.rugge@unipd.it](mailto:massimo.rugge@unipd.it)

**F Farinati**

Department of Surgical and Gastroenterological Sciences, University of Padova

**G Zaninotto**

Department of Surgical and Medical Sciences, University of Padova

### References

- 1 **Dinis-Ribeiro M, Lopes C, da Costa-Pereira A, et al.** A follow up model for patients with atrophic

- chronic gastritis and intestinal metaplasia. *J Clin Pathol* 2004;**57**:177–82.
- 2 **Dixon MF**, Genta RM, Yardley JH, *et al.* Classification and grading of gastritis. The updated Sydney system. International Workshop on the Histopathology of Gastritis, Houston 1994. *Am J Surg Pathol* 1996;**20**:1161–81.
  - 3 **Rugge M**, Correa P, Dixon MF, *et al.* Gastric mucosal atrophy: interobserver consistency using new criteria for classification and grading. *Aliment Pharmacol Ther* 2002;**16**:1249–59.
  - 4 **Rugge M**, Cassaro M, Di Mario F, *et al.* The long term outcome of gastric non-invasive neoplasia. *Gut* 2003;**52**:1111–16.
  - 5 **Fenoglio-Preiser C**, Carneiro F, Correa P, *et al.* Gastric carcinoma. In: Hamilton SR, Aaltonen LA, eds. *Pathology and genetics. Tumours of the digestive system*. Lyon: IARC Press, 2000:39–52.
  - 6 **Rugge M**, Cassaro M, Pennelli G, *et al.* Atrophic gastritis: pathology and endoscopy in the reversibility assessment. *Gut* 2003;**52**:1387–8.

## CALENDAR OF EVENTS

Full details of events to be included should be sent to Maggie Butler, Technical Editor JCP, The Cedars, 36 Queen Street, Castle Hedingham, Essex CO9 3HA, UK; email: maggie.butler2@btopenworld.com

### ACP Management Course for Pathologists, 2004

8–10 September 2004, Hardwick Hall Hotel, Sedgefield, County Durham, UK

Further details: V Wood, ACP Central Office, 189 Dyke Road, Hove, East Sussex BN3 1TL, UK. (Tel: +44 (0) 1273 775700; Fax: +44 (0) 1273 773303; Email: Jacqui@pathologists.org.uk)

### Combined Adult and Congenital Cardiovascular Pathology Course

8–10 November 2004, Imperial School of Medicine, National Heart and Lung Institute, London, UK

Further details: Short Course Office, National Heart and Lung Institute, Dovehouse Street, London SW3 6LY, UK. (Tel: +44 (0)20 7351 8172; Fax: +44 (0)20 7351 8246; Email: shourtcourse.NHLI@IC.AC.UK)

### Asian Pacific Association for Study of the Liver Biennial Conference

11–15 December 2004, New Delhi, India

Further details: Dr V Malhotra (General Secretary) or Dr P Sakhuja (Treasurer and Pathology Coordinator), Room 325, Academic Block, Department of Pathology, GB Pant Hospital, New Delhi 110002, India. (Tel: +91 11

23237455; Email: welcome@apaslindia2004.com; Website: www.apaslinzdia2004.com)

## BOOK REVIEW

### Medical Microbiology

Edited by C H Collins, P M Lyme, J M Grange, *et al.* Published by Hodder Arnold, 2003, £45.00 (paperback), pp 456. ISBN 0 34080 896 9

If ever asked the question “what are flippers, springers, and hard swells?” in the pub quiz then this book, the eighth edition of a venerated text that first appeared in 1964, is where you should turn for the answers. The new edition has enlisted the help of an American editor and author in a bid to include a North American perspective and, although there are nods in this direction (NCCLS susceptibility testing—for example), this is essentially a text that will appeal to a mostly UK centric audience. The book acknowledges that many microbiology laboratories, clinical or otherwise, still rely to a very great extent on traditional hands on benchwork and the detail in which this type of working is covered has always been this book’s strong point. However, in this new edition one senses a reluctance to bow to change and wave farewell to some old friends. Do we really need to know about the care and maintenance of glass Petri dishes (“still popular in some areas”); does anyone still use Stamp’s method for preserving cultures or the Henry technique in isolating listeria? Nevertheless, the book does cover automated and molecular techniques, but some are given more weight than others—for example, there is an in depth discussion of impedance instrumentation, whereas real time polymerase chain reaction is dealt with in a single paragraph. Diagrams to illustrate the principles behind some less widely known techniques might also have been of value.

The book has never confined itself to methods used by medical microbiologists and has always placed a strong emphasis on techniques used in food, water, and environmental laboratories. This is no bad thing because there is a considerable degree of overlap between the disciplines—clinical laboratories may wish to perform air or environmental sampling when investigating

outbreaks of nosocomial infection—for example, and biomedical scientists and medical microbiologists (especially those in training) would benefit from knowledge of how to assess foodstuffs for microbiological safety. Conversely, however, there are other areas where the clinical and non-clinical disciplines diverge a little too much, and the clinical fraternity is unlikely to find much interest in, for instance, performing spore counts on gelatin used in canned ham production or in sampling vats, hoppers, and pipework. Coverage of non-clinical methods has also encroached on the space devoted to culture and identification of medically important pathogens—methicillin resistant *Staphylococcus aureus* is breezed over in two short paragraphs and reference to glycopeptide resistance in enterococci is restricted to two statements that *Enterococcus casseliflavus* and *Enterococcus gallinarum* manifest low level resistance to vancomycin. Perhaps future editions of the book could have two iterations—one for food/water/environmental microbiologists, with less emphasis on clinical methods, and one for workers in clinical laboratories in which the food and other sections are reined in to a more appropriate level.

Despite these criticisms, there really is much to recommend this book, with handy chapters on laboratory safety, quality assurance, sterilisation and disinfection, enumeration of bacteria, and others, which are relevant to all laboratories. It would certainly be a worthwhile purchase for many laboratories (although not for virology laboratories: the book is a virus free zone), especially those where trainees are to be found. And flippers, springers, and hard swells? They are all types of can deformation produced by gas producing food spoilage organisms.

J R Kerr

## CORRECTION

**Distribution of constitutive (COX-1) and inducible (COX-2) cyclooxygenase in postviral human liver cirrhosis: a possible role for COX-2 in pathogenesis of liver cirrhosis.** Mohammed N A, El-Aleem S A, El-Hafiz H A, *et al.* *J Clin Pathol* 2004;**57**:350–4. The second author’s name should have been Abd El-Aleem S A.