

ORIGINAL ARTICLE

Evidence based criteria for the histopathological diagnosis of toxoplasmic lymphadenopathy

M Eapen, C F Mathew, K P Aravindan

J Clin Pathol 2005;58:1143–1146. doi: 10.1136/jcp.2005.026492

See end of article for authors' affiliations

Correspondence to: Professor K P Aravindan, Department of Pathology, Medical College, Calicut 673008, India; kparavind@sancharnet.in

Accepted for publication 14 March 2005

Aims: To formulate evidence based histopathological criteria for the diagnosis of acquired toxoplasmic lymphadenitis, in an area of high tuberculosis prevalence.**Methods:** Multiple histopathological parameters were assessed in a consecutive sample of biopsies from 68 patients presenting with lymphadenopathy with a duration of less than six months. Serum IgM enzyme linked immunosorbent assay was used as the standard reference test for the diagnosis of toxoplasmic lymphadenitis. The sensitivity, specificity, and likelihood ratios of various histological parameters were estimated.**Results:** The presence of microgranulomas ($p < 0.0001$), paracortical widening ($p = 0.006$), paracortical hyperplasia ($p = 0.02$), monocytoid B cells in sinuses ($p = 0.007$), lower than grade 2 macrogranuloma ($p = 0.002$), and the absence of giant cells ($p = 0.05$) were found to discriminate between IgM positive cases and IgM negative controls. Using a composite criterion—(1) presence of microgranulomas, (2) lower than grade 2 macrogranuloma, (3) absence of giant cells, and (4) follicular hyperplasia—toxoplasmic lymphadenitis can be diagnosed with a high degree of sensitivity (100%), specificity (96.6%), and positive likelihood ratio (29).**Conclusion:** Toxoplasma lymphadenitis can be diagnosed with a high degree of confidence using the specific histopathological criteria identified here.

The organism *Toxoplasma gondii* is a common cause of lymphadenopathy in adults. Studies have shown that infection can be suspected from histopathology of the lymph node, even though the primary diagnosis rests on the demonstration of specific antibodies in the serum. Several studies have correlated histological features in the lymph node with serology or polymerase chain reaction for the toxoplasma genome in the lymph nodes.^{1–5} These studies did not evolve specific evidence based criteria and left open a few questions such as: Do all patients with toxoplasmic lymphadenitis have the “typical” histopathological findings? Is there overlap in the histology of tuberculosis and toxoplasmosis because both are characterised by epithelioid granulomas?

“Several studies have correlated histological features in the lymph node with serology or polymerase chain reaction for the toxoplasma genome in the lymph nodes”

In developing countries, because of the high prevalence of tuberculosis and lack of easy diagnostic accessibility, it is possible that many cases of toxoplasmic lymphadenitis are being diagnosed as granulomatous lymphadenitis. This may lead to unnecessary and potentially toxic treatment for tuberculosis.

To clarify these questions, we used a design suited to evolve evidence based histopathological criteria. Various histological parameters were compared between toxoplasma positive and negative groups in a sample of consecutive lymph node biopsies.

METHODS AND SUBJECTS

Subjects

Inclusion criteria

Patients who had undergone lymph node biopsies in a referral hospital over an eight month period.

Exclusion criteria

(1) Metastatic lymph nodes, lymphoma, and nodes with caseation necrosis covering more than one fifth of the area of one histological section. (2) Nodes dissected during organ removal surgery. (3) Lymphadenopathy of more than six months' duration

Design

Diagnostic test evaluation.

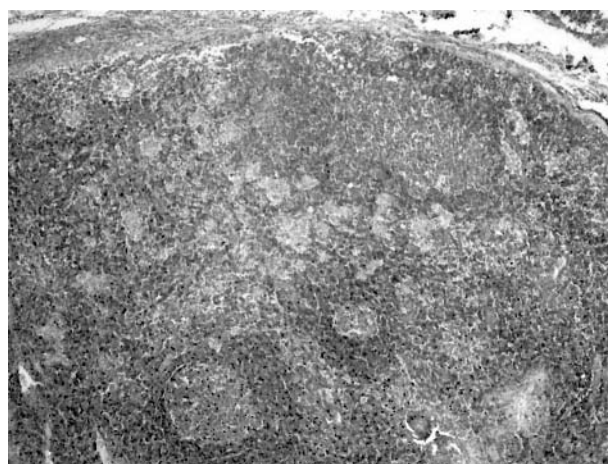


Figure 1 Toxoplasma lymphadenitis with follicular hyperplasia and microgranulomas in the paracortex. Haematoxylin and eosin staining; original magnification, $\times 100$.

Abbreviations: ELISA, enzyme linked immunosorbent assay

Reference standard

Toxoplasma IgM antibody positivity in the serum.

Methods

Study patients were called back within a month of undergoing surgery and 5 ml of blood was collected after informed consent, according to the institutional guidelines. Serum was separated immediately and stored at -20°C . At that time, detailed clinical information and investigation reports were obtained from each patient.

Pathological variables

After formalin fixation, sections were cut with a disposable knife, routinely processed, and stained with haematoxylin and eosin. All the observations were recorded blind to the histological diagnosis, and before serological testing for toxoplasma was undertaken. The presence or absence of the following histological variables was noted.

- (1) Periadentitis.
- (2) Cells in sinuses (plasma cells, eosinophils, neutrophils, lymphocytes, macrophages, monocytoïd B cells, epithelioid cells).
- (3) Follicles: (a) number, (b) distribution (cortical or entire node), (c) shape (round or irregular), (d) presence of prominent germinal centres, (e) mean diameter of germinal centre, (f) lymphocytic infiltration of germinal centres, (g) tingible body macrophages, (h) confluence of germinal centres, (i) vascularisation of germinal centres, (j) mantle zone prominence/onion peeling.
- (4) Paracortex: (a) widening, (b) hyperplasia (presence of immunoblasts and/or tingible body macrophages in the paracortex).
- (5) Microgranulomas (defined as collections of epithelioid cells with < 25 nuclei).
- (6) Macrogranulomas (defined as collections of epithelioid cells with > 24 nuclei).
- (7) Caseation necrosis.
- (8) Giant cells (Langhan's or foreign body type).
- (9) Microabscesses.
- (10) Vascular proliferation.
- (11) Apoptosis.

The above variables were graded wherever appropriate as 1 (seen in an occasional field), 2 (seen in about half the fields), and 3 (seen in most fields). Macrogranulomas were graded as

follows. Grade 1: less than three granulomas/section, with no granuloma having more than 50 epithelioid cell nuclei. Grade 2: three or more granulomas, with granulomas having more than 50 nuclei; no caseation necrosis. Grade 3: granulomas with caseation necrosis.

Toxoplasma antibody assay

All sera collected from patients were assayed for anti-toxoplasma IgM by enzyme linked immunosorbent assay (ELISA; IgM capture method; Dia pro Diagnostic Bioprobes, Milan, Italy).⁶ The assay is based on the principle of "IgM capture" where IgM class antibodies in the sample are first captured by the solid phase coated with antihuman IgM antibody. After washing away all other components of the sample (in particular IgG antibodies), in the second incubation bound anti-*Toxoplasma gondii* IgM are detected by the addition of a complex composed of *Toxoplasma gondii* specific native antigens, and a *Toxoplasma gondii* specific monoclonal antibody, labelled with horseradish peroxidase. After incubation, microwells are washed to remove unbound conjugate and then the chromogen/substrate is added. In the presence of bound conjugate the colourless substrate is hydrolysed to a coloured end product, the optical density of which is proportional to the amount of IgM *Toxoplasma gondii* specific antibodies present in the sample. The sensitivity is $> 98\%$ and the specificity $> 99\%$. A concentration of 50 IU/ml was used to discriminate between the positive and negative population.

Statistical analysis

The histopathological variables were compared between the two groups (toxoplasma IgM positive cases and toxoplasma IgM negative controls) by χ^2 analysis (Yates correction or Fisher's exact test applied where appropriate) for qualitative variables and the Student's *t* test or Kruskal Wallis test as appropriate for quantitative variables. The diagnostic efficacy (sensitivity, specificity, predictive values, and likelihood ratios) of variables with significant differences between the two groups was calculated.

RESULTS

Eighty consecutive patients fulfilling the inclusion and exclusion criteria were selected for our study. Serum was available for testing in 68 of these patients. The remainder were non-responders or patients whose serum was haemolysed. The histopathological diagnoses were: reactive hyperplasia, 37; reactive hyperplasia with microgranulomas, eight;

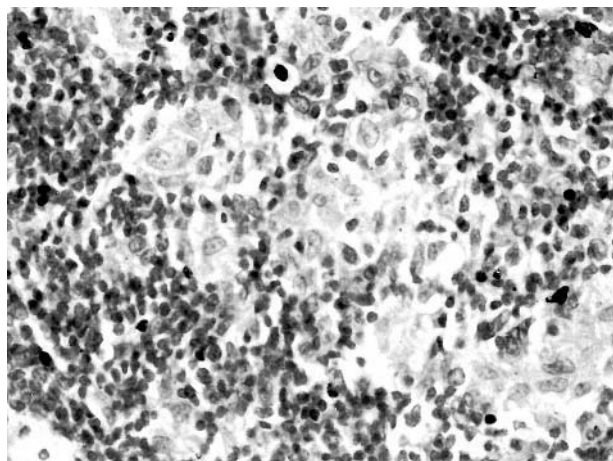


Figure 2 Microgranulomas containing less than 25 epithelioid cell nuclei. Haematoxylin and eosin staining; original magnification, $\times 400$.

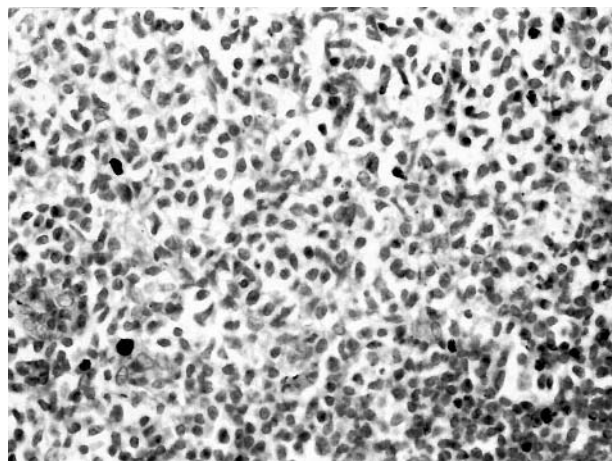


Figure 3 Monocytoïd B cells in sinuses. Haematoxylin and eosin staining; original magnification, $\times 400$.

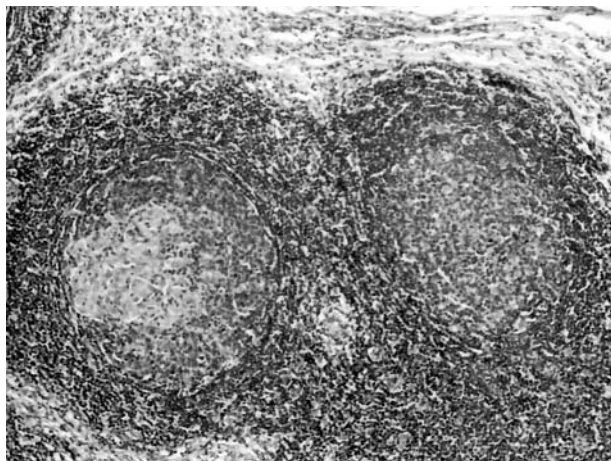


Figure 4 Epithelioid cells within a germinal centre in an anti-toxoplasma IgM negative case, which also had caseating granulomas. Haematoxylin and eosin staining; original magnification, $\times 200$.

granulomatous lymphadenitis, 15; Castleman's disease, three; and Kikuchi disease, five.

Clinical features and histopathology of toxoplasmosis

Nine patients tested positive for anti-toxoplasma IgM antibody. The clinical features were not unique. Fever was uniformly absent. The nodes showed moderate enlargement. Illness was of less than four months duration in all the patients. The nine cases showed a rather characteristic histology (fig 1). There was pronounced follicular hyperplasia, with the presence of microgranulomas (collections of less than 25 epithelioid cells; fig 2). Paracortical widening, paracortical hyperplasia, and vascular proliferation, characterised by many high endothelial venules, were seen in most cases. Sinus histiocytosis was not a prominent feature, although four of the nine cases showed at least focal distension of the sinuses by monocytoid B cells (fig 3). There were only few neutrophils, eosinophils, and plasma cells in the sinuses.

The distribution of microgranulomas varied from case to case. In one, there was just one microgranuloma abutting the mantle zone. In another, there was a diffuse scattering of these granulomas. In yet another, microgranulomas were distributed in a sinus pattern. The remaining positive cases showed microgranulomas in a predominantly paracortical location. An intrafollicular location was seen in only two cases. Incidentally, it was also seen in a case of toxoplasma negative granulomatous lymphadenitis with large granulomas and caseation (fig 4).

Macrogranulomas (collections of more than 24 epithelioid cells) were seen in three of the IgM positive cases. In all of them it was grade 1 (less than three/section). None of the

macrogranulomas in these three cases exceeded 50 cells. Caseation and giant cells were absent.

Comparison of the qualitative and quantitative histological variables showed only the following to be significantly different between the IgM positive and negative groups (*p* values of χ^2 test in parenthesis; for (e) and (f) only nodes containing epithelioid cells were considered). (a) Paracortical widening (*p* = 0.006); (b) paracortical hyperplasia (*p* = 0.02); (c) presence of microgranulomas (*p* < 0.0001); (d) monocytoid B cells in sinuses (*p* = 0.007); (e) lower than grade 2 macrogranuloma (*p* = 0.002); and (f) absence of giant cells (*p* = 0.05).

A composite criterion was derived from the above results that could efficiently discriminate toxoplasma lymphadenitis from other causes. This comprised the following parameters: (1) presence of microgranulomas, (2) lower than grade 2 macrogranuloma, (3) absence of giant cells, and (4) follicular hyperplasia with prominent germinal centres. The last parameter was included to discriminate toxoplasmosis from lymphomas with a granulomatous reaction. Table 1 shows the sensitivity, specificity, positive likelihood ratios, and post-test probabilities of the variables.

DISCUSSION

The histopathological triad of florid reactive follicular hyperplasia, clusters of epithelioid histiocytes, and focal sinusoidal distension by monocytoid B cells has been considered to be diagnostic of toxoplasmic lymphadenitis.^{2,3,5} According to our study, although highly specific (96.6%), this triad had a sensitivity of only 44.4%. The limiting factor is the presence of monocytoid B cells, which were seen in only four of the nine cases of toxoplasmosis. The sensitivity of the triad was 62.5% and the specificity was 91.3% in another study, which used polymerase chain reaction as the reference standard.⁵ However, this is not strictly comparable with our study because of the different reference standards used. Polymerase chain reaction as a reference standard for acute toxoplasmic lymphadenitis has the problem of being over-sensitive because it may pick up past infections. IgM ELISA is usually positive in all patients in the first three months,⁷ but may also be problematic on occasion because high antibody titres can persist for long periods.⁸ We tried to minimise this by limiting our subject selection to lymphadenopathy of less than six months duration.

"The most important component of our composite criterion is the presence of microgranulomas, which we defined as collections of epithelioid cells with less than 25 nuclei"

The composite criterion that we propose has a sensitivity of 100%, specificity of 96.6%, and a positive likelihood ratio of 29. The post-test probability is 0.82, up from a pre-test probability (prevalence) of 0.13.

Table 1 Diagnostic efficacy parameters for significant histopathological variables

Parameter	Sensitivity (95% CI)	Specificity (95% CI)	Positive likelihood ratio (95% CI)	Post-test probability
Paracortical widening	100 (72.4 to 100)	55.9 (51.7 to 55.9)	2.3 (1.6 to 3.0)	0.26
Paracortical hyperplasia	55.6 (28.6 to 79.3)	84.7 (80.6 to 88.4)	3.6 (1.6 to 8.4)	0.36
Presence of microgranulomas	100 (74.1 to 100)	88.1 (84.2 to 88.1)	8.4 (3.8 to 15.0)	0.56
Monocytoid B cells in sinuses	44.4 (20.9 to 66.2)	93.2 (89.6 to 96.5)	6.6 (2.0 to 22.0)	0.50
Lower than grade 2 macrogranuloma	100 (77.7 to 100)	69.2 (61.6 to 76.9)	4.3 (1.5 to 9.5)	0.75
Absence of giant cells	100 (62.9 to 100)	69.2 (53.8 to 69.2)	3.3 (1.4 to 6.4)	0.69
Classic diagnostic triad	44.4 (21.7 to 59.6)	96.6 (93.1 to 98.9)	13.1 (2.8 to 62.0)	0.66
Composite criterion	100 (62.9 to 100)	96.6 (87.2 to 99.4)	29.0 (6.7,77.0)	0.82

CI, confidence interval.

Take home messages

- We have devised a composite criterion—(1) presence of microgranulomas, (2) lower than grade 2 macrogranuloma, (3) absence of giant cells, and (4) follicular hyperplasia—that can diagnose toxoplasmic lymphadenitis with a high degree of sensitivity (100%), specificity (96.6%), and positive likelihood ratio (29)
- These criteria should be tested further in prospective studies

The most important component of our composite criterion is the presence of microgranulomas, which we defined as collections of epithelioid cells with less than 25 nuclei. Larger collections, which we called macrogranulomas, are either absent or if present only of grade 1 (less than three/section, never containing more than 50 cell nuclei, and never having caseation). Defined thus, grade 1 macrogranulomas are probably the result of coalescence of occasional microgranulomas. Among other significant discriminators between cases and controls, paracortical widening and hyperplasia have lower specificity and sensitivity, respectively. Moreover, these are relatively subjective and liable to interobserver variation. Follicular hyperplasia with prominent germinal centres was included in the criterion primarily for differentiation from lymphomas, which sometimes show a microgranulomatous reaction.⁹ However, it should be remembered that interfollicular Hodgkin disease and rare cases of mucosa associated lymphoid tissue lymphoma can have a combination of reactive follicles and epithelioid clusters.

The occurrence of epithelioid cells within germinal centres, which is thought to be a specific feature of toxoplasmosis,⁹ was not found to have significance in our study. It was seen in two cases of toxoplasmosis and in an IgM negative case (probably tuberculosis). Although our sample included five cases of Kikuchi disease, none of them tested positive for IgM toxoplasma antibody, unlike the case reports by Kikuchi *et al.*¹⁰

There were two cases that showed all the features of toxoplasma lymphadenitis according to our combined criterion, but were negative for IgM. These could be patients recovering from acute infection or true negatives with as yet undetermined causes. Epithelioid cell clusters and monocytoïd B cells can occur in cases of cat scratch disease, sometimes in the absence of abscesses, and such cases can be confused with toxoplasmosis.¹¹

In conclusion, toxoplasmic lymphadenitis can be diagnosed with a high degree of confidence using the specific histopathological criteria that we have laid down. These criteria should be tested further in prospective studies.

Authors' affiliations

M Eapen, C F Mathew, Medical College, Calicut 673008, India
K P Aravindan, Department of Pathology, Medical College, Calicut 673008, India

REFERENCES

- 1 Dorfman RF, Remington JS. Value of lymph-node biopsy in the diagnosis of acute acquired toxoplasmosis. *N Engl J Med* 1973;**289**:878–81.
- 2 Miettinen M, Saxen L, Saxen E. Lymph node toxoplasmosis. Follow-up of 237 histologically diagnosed and serologically verified cases. *Acta Med Scand* 1980;**208**:431–6.
- 3 Miettinen M. Histological differential diagnosis between lymph node toxoplasmosis and other benign lymph node hyperplasias. *Histopathology* 1981;**5**:205–16.
- 4 Tuzuner N, Dogusoy G, Demirkesen C, *et al.* Value of lymph node biopsy in the diagnosis of acquired toxoplasmosis. *J Laryngol Otol* 1996;**110**:348–52.
- 5 Lin MH, Kuo TT. Specificity of the histopathological triad for the diagnosis of toxoplasmic lymphadenitis: polymerase chain reaction study. *Pathol Int* 2001;**51**:619–23.
- 6 Naot Y, Remington JS. An enzyme-linked immunosorbent assay for detection of IgM antibodies to *Toxoplasma gondii*: use for diagnosis of acute acquired toxoplasmosis. *J Infect Dis* 1980;**142**:757–66.
- 7 Montoya JG, Remington JS. Studies on the serodiagnosis of toxoplasmic lymphadenitis. *Clin Infect Dis* 1995;**20**:781–9.
- 8 Brooks RG, McCabe RE, Remington JS. Role of serology in the diagnosis of toxoplasmic lymphadenopathy. *Rev Infect Dis* 1987;**9**:1055–62.
- 9 Miettinen M, Franssila K. Malignant lymphoma simulating lymph node toxoplasmosis. *Histopathology* 1982;**6**:129–40.
- 10 Kikuchi M, Yoshizumi T, Nakamura H. Necrotizing lymphadenitis: possible acute toxoplasmic infection. *Virchows Arch A Pathol Anat Histol* 1977;**376**:247–53.
- 11 Kojima M, Hosomura Y, Itoh H, *et al.* Monocytoïd B lymphocytes and epithelioid cell clusters in abscess-forming granulomatous lymphadenitis. With special reference to cat scratch disease. *Acta Pathol Jpn* 1991;**41**:363–8.