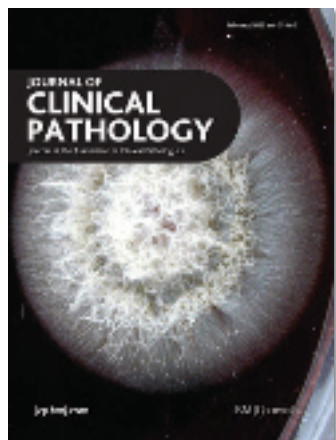



Cover image: Blastomyces colony

## Contents

### My approach

- 145** Calcification in breast lesions: pathologists' perspective *G M Tse, P-H Tan, A L M Pang, A P Y Tang, H S Cheung*
- 152** My approach to and thoughts on the typing of ovarian carcinomas *W G McCluggage*

### Review

- 164** Expansion of a mutated clone: from stem cell to tumour *S J Leedham, N A Wright*


### ACP best practice

- 172** Best practice in macroscopic examination of gastric resections *S A Pritchard*

### Original articles

- 179** Traditional urinary cytology and tyrosinase RT-PCR in metastatic melanoma patients: correlation with clinical status *P Savoia, S Osella-Abate, A Comessatti, T Nardò, C Marchiò, D Pachioni, P Quaglino, M G Bernengo*
- 184** Cyclin E confers a prognostic value in premenopausal breast cancer patients with tumours exhibiting an infiltrative growth pattern *P Berglund, M Stighall, K Jirström, L Rydén, M Fernö, B Nordenskjöld, G Landberg*
- 192** p53 protein expression and genetic mutation in two primary cell types in pulmonary sclerosing haemangioma *Y Wang, S-D Dai, F-J Qi, H-T Xu, E-H Wang*
- 197** Oestrogen receptors  $\alpha$  and  $\beta$  show different associations to clinicopathological parameters and their co-expression might predict a better response to endocrine treatment in breast cancer *S Borgquist, C Holm, M Stendahl, L Anagnostaki, G Landberg, K Jirström*

February 2008 Vol 61 No 2

- 203**  Molecular alterations of *KIT* and *PDGFRA* in GISTs: evaluation of a Portuguese series *A L Gomes, A Gouveia, A F Capelinha, D de la Cruz, P Silva, R M Reis, A Pimenta, J M Lopes*
- 209** Diagnostic value of combining immunostaining for CD3 and nuclear morphometry in mycosis fungoides *M L Lira, A A Schenka, L A Magna, A C Cotta, M L Cintra, E M de Souza, P Brousset, J Vassallo*
- 213** Bone marrow trephine combined with immunohistochemistry is superior to bone marrow aspirate in follow-up of myeloma patients *R Joshi, D Horncastle, K Elderfield, I Lampert, A Rahemtulla, K N Naresh*
- 217** BNIP3 expression in endometrial cancer relates to active hypoxia inducible factor 1 $\alpha$  pathway and prognosis *A Giatromanolaki, M I Koukourakis, K C Gatter, A L Harris, E Sivridis*
- 221** Development of real time PCR to detect *Toxoplasma gondii* and *Borrelia burgdorferi* infections in postal samples *A W L Joss, R Evans, S Mavin, J Chatterton, D O Ho-Yen*
- 225** Best of the web in pathology: a practical guide to finding specific pathology resources on the internet *J Boehm*
- 
- ### Short reports
- 233** Infective endocarditis incidentally discovered by pathological examination *H Lepidi, J-P Casalta, F Gouriet, F Collart, G Habib, D Raoult*
- 235** Is microscopic examination of hysterectomy specimens removed for clinically benign disease necessary? *T Andrews, H Monaghan*
- 
- ### PostScript
- 237** Letters to the editor



This article has been chosen by the Editor to be of specialist interest or importance and is freely available online.



Articles carrying the Unlocked Logo are freely available online under the BMJ Journals unlocked scheme. See <http://jcp.bmj.com/info/unlocked.dtl>



[www.publicationethics.org.uk](http://www.publicationethics.org.uk)  
This journal is a member of and subscribes to the principles of the Committee on Publication Ethics