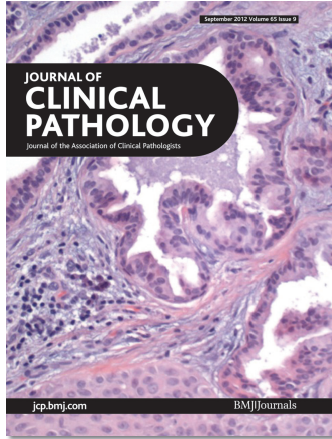

# Journal of Clinical Pathology



Cover legend: A complex adnexal tumors of the skin (CATS) showing a mixture of a proliferating pilar tumor (PPT) and syringocystadenoma papilliferum (SCAP). The glandular component is composed of glands that are lined by tall columnar cells with decapitated secretions, multiple intraluminal infoldings and pink homogenous secretions in their lumina. From London *et al*, see page 819.

Receive regular table of contents by email.  
Register using this QR code.



## Contents

### Review

- 771** Current issues in diagnostic breast pathology  
*R A Walker, A Hanby, S E Pinder, J Thomas, I O Ellis*



### Original articles

- 786** The UK NEQAS for Molecular Genetics scheme for gastrointestinal stromal tumour: findings and recommendations following four rounds of circulation  
*N A C S Wong, Z C Deans, S C Ramsden*
- 791** Predictors of duodenal bulb biopsy performance in the evaluation of coeliac disease in children  
*P Tanpowpong, S Broder-Fingert, A J Katz, C A Camargo Jr*
- 795** Expression of cyclin-dependent kinase 2-associated protein 1 confers an independent prognosticator in nasopharyngeal carcinoma: a cohort study  
*L-C Wu, Y-L Chen, W-R Wu, C-F Li, H-Y Huang, S-W Lee, S-L Chang, C-Y Lin, Y-H Chen, H-P Hsu, P-J Lu, Y-L Shiu*
- 802** Rsf-1/HBXAP overexpression is independent of gene amplification and is associated with poor outcome in patients with urinary bladder urothelial carcinoma  
*P-I Liang, L-C Wu, J J-C Sheu, T-F Wu, K-H Shen, Y-H Wang, W-R Wu, Y-L Shiu, H-Y Huang, H-P Hsu, Y-H Chen, L-T Chen, C-F Li, A C Liao*
- 808** Expression and prognostic significance of vascular endothelial growth factor receptor 1 in hepatocellular carcinoma  
*T Li, Y Zhu, C-y Qin, Z Yang, A Fang, S Xu, W Ren*
- 815** Isolated cutaneous manifestation of IgG<sub>4</sub>-related disease  
*T Hatori, T Miyayama, O Tago, M Udagawa, Y Kamiyama, Y Nagai, O Ishikawa*
- 819** Complex adnexal tumours of the skin: a report of three cases and review of literature  
*V London, P Saadat, M S Vadmal*
- 823** Immunophenotypic heterogeneity of normal plasma cells: comparison with minimal residual plasma cell myeloma  
*D Liu, P Lin, Y Hu, Y Zhou, G Tang, L Powers, L J Medeiros, J L Jorgensen, S A Wan*

## September 2012 Volume 65 Issue 9


- 830** Intestinal *Staphylococcus spp.* and virulent features associated with coeliac disease  
*E Sánchez, C Ribes-Koninx, M Calabuig, Y Sanz*
- 835** Use of matrix assisted laser desorption ionisation-time of flight mass spectrometry in a paediatric clinical laboratory for identification of bacteria commonly isolated from cystic fibrosis patients  
*A P Desai, T Stanley, M Atuan, J McKey, J J Lipuma, B Rogers, R Jerris*


### Short report

- 839** Expression of melanoma differentiation associated gene 5 is increased in human gastric mucosa infected with *Helicobacter pylori*  
*T Tatsuta, T Imaizumi, T Shimoyama, M Sawaya, T Kunikazu, T Matsumiya, H Yoshida, K Satoh, S Fukuda*
- 844** A170P mutation in *SHOX* gene in a patient not presenting with Madelung deformity  
*M Álvarez-Mora, I Madrigal, L Rodríguez-Revenga, A Mur, D Calvo, J Pascual i Bardají, M Milà*
- 847** Is there a rationale to record lymphatic invasion in node-positive colorectal cancer?  
*J Betge, N I Schneider, M J Pollheimer, R A Lindtner, P Kornprat, A Schlemmer, P Rehak, C Langner*

### PostScript

- 851** Correspondence
- 861** Book review
- 861** Retraction
- 863** Obituary

 This article has been chosen by the Editor to be of special interest or importance and is freely available online.

 Articles carrying the Unlocked Logo are freely available online under the BMJ Journals unlocked scheme.  
See <http://jcp.bmj.com/info/unlocked.dtl>

C O P E COMMITTEE ON PUBLICATION ETHICS

This journal is a member of and subscribes to the principles of the Committee on Publication Ethics  
[www.publicationethics.org.uk](http://www.publicationethics.org.uk)

 equator network

 recycle  
When you have finished with this please recycle it