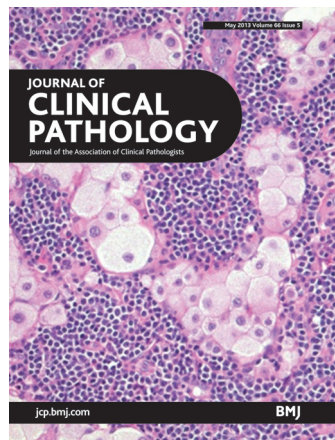

# Journal of Clinical Pathology



Cover legend: Metastatic balloon cell melanoma in sinusoids of a lymph node. Courtesy of Dr Danny Ghazarian, University of Toronto, Canada.

## Contents

### Editorial

- 361** Consultant leaders and delivery of high quality pathology services *D J Unsworth, R J Lock*

### Review

- 362** The role of amyloid  $\beta$  in the pathogenesis of Alzheimer's disease *B J Gilbert*

### ACP best practice

- 367** Recent advances in management of alkaptonuria (invited review; best practice article) *L R Ranganath, J C Jarvis, J A Gallagher*

### Original articles

- 374** Immunohistochemistry of deparaffinised sections using antigen retrieval with microwave combined pressure cooking versus immunofluorescence in the assessment of human renal biopsies *S Shi, P Zhang, Q Cheng, J Wu, J Cui, Y Zheng, X-Y Bai, X Chen*
- 381** Comparison of molecular testing methods for the detection of *EGFR* mutations in formalin-fixed paraffin-embedded tissue specimens of non-small cell lung cancer *F Lopez-Rios, B Angulo, B Gomez, D Mair, R Martinez, E Conde, F Shieh, J Tsai, J Vaks, R Current, H J Lawrence, D G de Castro*
- 386** Notch1-Hes1 signalling axis in the tumourigenesis of biliary neuroendocrine tumours *K Harada, Y Sato, H Ikeda, M Hsu, S Igarashi, Y Nakanuma*
- 392** Post-transplant lymphoproliferative disorders in liver transplant recipients: a clinicopathological study *R Cheuk-lam Lo, See-ching Chan, Kwong-leung Chan, A Kwok-shing Chiang, Chung-mau Lo, Irene Oi-lin Ng*
- 399** Eosinophilic oesophagitis in children: responders and non-responders to swallowed fluticasone *R Boldorini, F Mercalli, G Oderda*
- 403** The stem cell marker CD133 is highly expressed in sessile serrated adenoma and its borderline variant compared with hyperplastic polyp *M Mohammadi, M Bzorek, J H Bonde, H J Nielsen, S Holck*
- 409** SP3, a reliable alternative to HercepTest in determining HER-2/*neu* status in breast cancer patients *T M D'Alfonso, Y-F Liu, Z Chen, Y-B Chen, A Cimino-Mathews, S J Shin*

## May 2013 Volume 66 Issue 5

- 415** Faecal haemoglobin concentration is related to severity of colorectal neoplasia *J Digby, C G Fraser, F A Carey, P J McDonald, J A Strachan, R H Diamant, M Balsitis, R J C Steele*
- 420** Prognostic impact of concordant and discordant cytomorphology of bone marrow involvement in patients with diffuse, large, B-cell lymphoma treated with R-CHOP *H Shim, J-I Oh, S H Park, S Jang, C-J Park, J Huh, C Suh, H-S Chi*
- 426** Who makes uric acid stones and why—observations from a renal stones clinic *E M Stansbridge, D G Griffin, V Walker*

### Viewpoint

- 432** The role of the physician in laboratory medicine: a European perspective *S A Misbah, V Kolekinou, K Jeffery, W Oosterhuis, B Shine, A Schuh, T Theodoridis*

### Short reports


- 438** Extreme hyperferritinaemia; clinical causes *M A Crook, P L C Walker*
- 441** The somatic affairs of *BRAF*: tailored therapies for advanced malignant melanoma and orphan non-V600E (V600R-M) mutations *G Ponti, G Pellacani, A Tomasi, F Gelsomino, A Spallanzani, R Depenni, S Al Jalbout, L Simi, L Garagnani, S Borsari, A Conti, C Ruini, A Fontana, G Luppi*
- 446** Amplification refractory mutation system-PCR is essential for the detection of chimaeras with a minor allele population: a case report *E J Won, H R Park, T S Park, S H Oh, M G Shin, J H Shin, S P Suh, D W Ryang, J T Park, D Cho*


### Postscript

- 449** Correspondence
- 455** Book review
- 455** Correction

Receive regular table of contents by email.  
Register using this QR code.



 This article has been chosen by the Editor to be of special interest or importance and is freely available online.

 This article has been made freely available online under the BMJ Journals Open Access scheme. See <http://jcp.bmj.com/site/about/guidelines.xhtml#open>

**C O P E** COMMITTEE ON PUBLICATION ETHICS

This journal is a member of and subscribes to the principles of the Committee on Publication Ethics  
[www.publicationethics.org.uk](http://www.publicationethics.org.uk)

 equator network

 recycle  
When you have finished with this please recycle it