

Journal of Clinical Pathology



Cover legend: A case of a trichoblastoma resembling the outline of a "scorpion".

Kindly supplied by Dr Danny Ghazarian, Toronto General Hospital, and University of Toronto, Canada.

Receive regular table of contents by email.
Register using this QR code.



This article has been chosen by the Editor to be of special interest or importance and is freely available online.

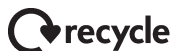

This article has been made freely available online under the BMJ Journals Open Access scheme. See <http://jcp.bmj.com/site/about/guidelines.xhtml#open>

C O P E COMMITTEE ON PUBLICATION ETHICS

This journal is a member of and subscribes to the principles of the Committee on Publication Ethics
<http://publicationethics.org/>

equator
network




When you have finished with this please recycle it

Contents

Editorial

- 289 Why are we still measuring red cell folate instead of just serum folate? *T S Pillay, N M Oosthuizen*

Review

- 290 An update on vulvar intraepithelial neoplasia: terminology and a practical approach to diagnosis
 *M C Reyes, K Cooper*

Original articles

- 295 EGFR expression in pancreatic adenocarcinoma. Relationship to tumour morphology and cell adhesion proteins *A Handra-Luca, P Hammel, A Sauvanet, C Lesty, P Ruszniewski, A Couvelard*
- 301 PIAS γ expression in relation to clinicopathological, tumour factors and survival in indigenous black breast cancer women *A Agboola, A Musa, A Banjo, B Ayode, M Deji-Agboola, C Nolan, E Rakha, I Ellis, A Green*
- 307 Association of HER1 amplification with poor prognosis in well differentiated gastric carcinomas *C Kandel, F Leclair, C Bou-Hanna, C L Laboisie, J-F Mosnier*
- 313 Downgrading of biopsy based Gleason score in prostatectomy specimens *K M Treurniet, D Trudel, J Sykes, A J Evans, A Finelli, T H Van der Kwast*
- 319 Fascin and cyclin D1 immunoreactivity in non-neoplastic vulvar squamous epithelium, vulvar intraepithelial neoplasia and invasive squamous carcinoma: correlation with Ki67 and p16 protein expression *C J R Stewart, M L Crook*
- 326 Epstein-Barr virus is rarely associated with diffuse large B cell lymphoma in Taiwan and carries a trend for a shorter median survival time *S-T Chang, Y-H Lu, C-L Lu, S-F Weng, S-H Lin, S-Y Kuo, Y-T Chuang, K Takeuchi, K Ohshima, S-S Chuang*
- 333 Phosphorylated Akt expression is a prognostic marker in early-stage non-small cell lung cancer *P Y Yip, W A Cooper, M R J Kohonen-Corish, B P C Lin, B C McCaughan, M J Boyer, J G Kench, L G Horvath*

April 2014 Volume 67 Issue 4

- 341 Full blood count normal reference values for adults in France *X Troussard, S Vol, E Cornet, V Bardet, J-P Couaillac, C Fossat, J-C Luce, E Maldonado, V Siguret, J Tichet, O Lantieri, J Corberand, for the French-Speaking Cellular Hematology Group (Groupe Francophone d'Hématologie Cellulaire, GFHC)*
- 345 Reducing inpatient heritable thrombophilia testing using a clinical decision-making tool *T W Smith, D Pi, M Hudoba, A Y Y Lee*
- 350 Serum pepsinogen reference intervals in apparently healthy Chinese population with latex enhanced turbidimetric immunoassay *M Huang, A-G Tang, S Mu, J-J Yang, Z-Y Xiang, B Liu, J-J Yang*
- 355 Male hypercalciuric stone formers with low renal calcium reabsorption *V Walker, P Cook, D G Griffin*
- 361 Matrix-assisted laser desorption ionisation time-of-flight mass spectrometry for identification of clinically significant bacteria that are difficult to identify in clinical laboratories *S K P Lau, B S F Tang, J L L Teng, T-M Chan, S O T Curreem, R Y Y Fan, R H Y Ng, J F W Chan, K-Y Yuen, P C Y Woo*

Short reports

- 367 The diagnostic challenge of congenital dyserythropoietic anaemia: two cases of 'CDA type II' *S Dukka, M-J King, Q A Hill*
- 370 The impact of pulmonary bone component embolism: an autopsy study *M S Detmer, N Willi, T Thiesler, P Ochsner, G Cathomas*

PostScript

- 375 Correspondence
- 380 Letter to the Editor