



OPEN ACCESS

Web based pathology assessment in RTOG 98-04

Wendy A Woodward,¹ Nour Sneige,¹ Kathryn Winter,² Henry Mark Kuerer,¹ Clifford Hudis,³ Eileen Rakovitch,⁴ Barbara L Smith,⁵ Lori J Pierce,⁶ Isabelle Germano,⁷ Anthony T Pu,⁸ Eleanor M Walker,⁹ David Lawrence Grisell,¹⁰ Julia R White,¹¹ Beryl McCormick,³ for the Radiation Therapy Oncology Group (RTOG)

► Additional material is published online only. To view please visit the journal online (<http://dx.doi.org/10.1136/jclinpath-2014-202370>).

For numbered affiliations see end of article.

Correspondence to

Dr Beryl McCormick, Memorial Sloan-Kettering Cancer Center, 1275 York Avenue, New York, NY 10065, USA; mccormib@mskcc.org

Received 15 April 2014

Revised 2 June 2014

Accepted 8 June 2014

Published Online First

2 July 2014

ABSTRACT

Aims Radiation Therapy Oncology Group 98-04 sought to identify women with ‘good risk’ ductal carcinoma in situ (DCIS) who receive no significant benefit from radiation. Enrolment criteria excluded close or positive margins and grade 3 disease. To ensure reproducibility in identifying good risk pathology, an optional web based teaching tool was developed and a random sampling of 10% of submitted slides were reviewed by a central pathologist.

Methods Submitting pathologists were asked to use the web based teaching tool and submit an assessment of the tool along with the pathology specimen form and DCIS H&E stained slide. Per protocol pathology was centrally reviewed for 10% of the cases.

Results Of the 55 DCIS cases reviewed, three had close or positive margins and three were assessed to include grade 3 DCIS, therefore 95% of DCIS cases reviewed were correctly graded, and 89% reviewed were pathologically appropriate for enrolment. Regarding the teaching tool, 13% of DCIS cases included forms that indicated the website was used. One of these seven who used the website submitted DCIS of grade 3.

Conclusions Central review demonstrates high pathological concordance with enrolment eligibility, particularly with regard to accurate grading. The teaching tool appeared to be underused.

INTRODUCTION

With the growing acceptance of mammography as a screening tool, non-palpable ductal carcinoma in situ (DCIS) is being diagnosed with a frequency of 20–25% in large breast practices. At the time Radiation Therapy Oncology Group (RTOG) 98-04 opened, retrospective studies suggested that good risk disease, that is, small lesions, with a low-grade pathology classification, might be effectively treated with radiation or with observation.^{1–3} Among randomised trials studying the benefit of postlumpectomy radiation therapy for DCIS, all ultimately demonstrated a benefit to postlumpectomy radiation for all cohorts.^{4–15} Around the time the RTOG 98-04 was designed, two of these had been reported.^{9–11} The National Surgical Adjuvant Breast and Bowel Project (NSABP) B-17 trial stratified patients by age, presence or absence of lobular carcinoma in situ, presence or absence of an axillary node dissection, and method of detection, that is, palpable mass versus mammogram only. Size, margins and pathological grade, recognised ultimately as important selection factors for possible treatment with observation only, were not factors in that trial.⁹ The NSABP B-24 trial, placed all

patients on radiation and then randomised them to post-radiation observation or tamoxifen.¹¹ Thus, neither trial addressed the question of the efficacy of no radiation in a subset of good-risk patients with DCIS. RTOG 98-04 was designed to address this gap in knowledge.

Multiple classification systems for DCIS have been proposed to assess prognostic factors such as size, extent of disease, margins and pathology grade; acceptance of uniform criteria for these factors, however, has not been achieved. Prior to the initiation of RTOG 98-04, a consensus conference was held with the purpose of defining pathological criteria for this disease. A consensus was reached by the participating pathologists and this working system was a starting point to assure standardisation in defining cases of pathological ‘good-risk’ disease. Using this consensus,¹⁶ a ‘teaching’ set of photomicrographs illustrating key diagnostic features of low, intermediate and high grade lesions was prepared and made available on the RTOG website as a resource for the designated pathologist from participating institutions. The consensus¹⁶ forms the basis of the current DCIS grading guidelines endorsed by the College of American Pathologists (CAPs), and this RTOG teaching website is referenced in the CAP guidelines.¹⁷ In RTOG 98-04, mandatory credentialing was not a requirement for study participation. However, slides from a random sample of 10% of patients on the study were retrospectively collected and reviewed by a dedicated breast pathologist. Herein the results of this sample review and the use of the teaching tool are reported.

METHODS

The definition of ‘good risk’ DCIS used the guidelines accepted at a classification consensus conference of DCIS.¹⁶ Patients were ineligible if the DCIS was high grade, >2.5 cm in greatest diameter as measured on the preoperative mammogram or pathological specimen, or had final pathological margin <3 mm. High histological grade was defined by the presence of either of two features: (1) high nuclear grade, defined as nuclear size >2.5 times lymphocyte or benign ductal epithelial cell nuclei, marked pleomorphism, irregular chromatin with single or multiple nucleoli and conspicuous mitoses, or (2) necrosis, defined by the presence of ghost cells with karyorrhectic debris, in a third or greater of the neoplastic ducts.

Specimen handling recommendations provided in RTOG 98-04 are described in online supplementary methods (document 1). Grading criteria were



Open Access
Scan to access more
free content



CrossMark

To cite: Woodward WA, Sneige N, Winter K, *et al.* *J Clin Pathol* 2014;**67**:777–780.

explicitly defined. Low grade nuclei (NG 1) applied to lesions with monotonous nuclei, size 1.5–2.0 normal red blood cell (RBC) or duct epithelial cell nucleus dimensions, which usually exhibit diffuse, finely dispersed chromatin with only occasional nucleoli and mitotic figures. NG 1 was further defined as usually associated with polarisation of constituent cells. Importantly, the presence of nuclei that were of similar size but were pleomorphic precluded a low grade classification. High-grade nuclei (NG 3) classification was applied to nuclei that were markedly pleomorphic, usually >2.5 RBC or duct epithelial cell nuclear dimensions, and usually demonstrated vesicular and irregular chromatin distribution and prominent, often with multiple nucleoli mitosis may be conspicuous. Nuclei that were neither NG 1 nor NG 3 were to be assigned to intermediate grade nuclei (NG 2). Any central zone necrosis within a duct, usually exhibiting a linear pattern within ducts if sectioned longitudinally was considered comedonecrosis. Punctate necrosis was defined as non-zonal type necrosis, defined as foci of individual cell necrosis visible under 10×. The required microscopic examinations included: (1) extent of DCIS (determined by number of sections containing DCIS as well as the largest dimension of DCIS lesion on a glass slide) (2) nuclear grade, (3) necrosis, (4) margins of resection (closest ≥ 3 –9 mm, ≥ 10 mm or a re-excision margin), (5) cell polarisation, (6) architectural patterns, and (7) the relationship of calcifications, when present, to the DCIS.

In order to improve reproducibility of histological criteria, a ‘teaching’ set of photomicrographs illustrating key diagnostic features of low/intermediate and high grade lesions was prepared by the designated RTOG breast central pathologist (NS) and made available on the RTOG website (<http://www.rtog.org/LinkClick.aspx?fileticket=G4Pamvh2mBg%3d&tabid=290>). Of note, this teaching set was selected from a group of DCIS cases that were the subject of a consensus review and all grading had been agreed upon by all participants from the study.¹⁵ This was provided as a resource for the designated pathologist from participating institutions; however, mandatory credentialing was not a requirement for study participation. A random sampling of 10% of cases (n=62) were requested for review by the central RTOG breast pathologist for the study (NS) to assess the success of the teaching tool in educating pathologists in the assignment of low or intermediate histological grade as defined in this protocol. Standard pathology submission forms as well as a teaching tool assessment form were expected to be submitted with the slides and were reviewed in the central sampling review. Pathology discrepancies identified did not render patients ineligible.

RESULTS

Results are summarised in [figure 1](#). Of the 62 requested cases, correct slides were submitted for 60, of which 5/60 (8%) had no DCIS on the slide. In three cases, slides submitted were from negative re-excisions and documented adequate margin per protocol. Fifty-two of 55 cases (95%) with DCIS slides available for review were grade 1 or grade 2 DCIS. Three of 55 (5%) were grade 3 DCIS. Of the 52 grade 1/2 DCIS cases, 3 had close or positive margins, therefore 49/55 cases (89%) reviewed were pathologically appropriate for enrolment based on the data available for review.

Regarding the teaching tool, 7/55 (13%) cases with DCIS slides included the forms intended to be returned with the slides that included responses that indicated the website was used. Six of these seven submitted DCIS of grade 1 or 2. One of the three slides that were found to contain grade 3 DCIS on

central review included documentation that the website was used.

DISCUSSION

Grading criteria for DCIS are complex and have changed over time. Uniform, reproducible grading criteria are critical for clinical trials basing randomisation and treatment strategy on these findings. State of the science guidelines were provided to participants in the protocol for RTOG 98-04 and on central review, 95% of cases were correctly graded as grade 1 or grade 2. While significant efforts were made to provide additional tools to pathologists to ensure accurate uniform grading, these appear to be underused and thus a direct benefit for this intervention could not be measured. Strategies for increasing awareness and use of similar tools in future studies are needed.

While nuclear grade and comedonecrosis have been strongly associated with increased risk of ipsilateral breast recurrence after lumpectomy alone in many studies,^{4 14 18} heterogeneity of populations and methods make consensus regarding true risk elusive.^{2 19} Length of follow-up may be a critical factor in this issue as high-grade lesions have been reported to recur earlier.²⁰ Four previously reported randomised trials comparing lumpectomy alone with lumpectomy and whole breast radiation have recently been reviewed by the Early Breast Cancer Trialists’ Collaborative Group.⁷ This overview included trials by the NSABP^{9 10 18} and the European Organization for Research and Treatment of Cancer^{4–6 13} which centrally reviewed >75% of cases, as well as the SweDCIS (Swedish DCIS)^{8 14} and UK/Australia New Zealand DCIS,¹² which centrally reviewed 25% and 0%, respectively. While not compared directly, they report that among 1794 patients treated with lumpectomy alone, the 10-year ipsilateral breast cancer recurrence was 21.7%, 24.8% and 32.2% for DCIS *histological* grade low, intermediate and high, respectively.⁷ Among 1617 women treated with lumpectomy alone evaluated by *nuclear* grade, the 10-year ipsilateral breast cancer recurrence was 28.4%, 29.8% and 33.1% for DCIS nuclear grade low, intermediate and high, respectively. As reported in each trial individually, in all cohorts there was a significant benefit to radiotherapy.⁷ In contrast, recent retrospective series from large centres failed to show an association between grade and presence of necrosis with risk of local failure.^{21–23} However these cohorts included patients who received radiotherapy and the Early Breast Cancer Trialists’ Collaborative Group meta-analysis suggests equal benefit among patients of all grades who receive radiation potentially confounding these results. While many factors may contribute to these heterogeneous results, standardisation of pathological assessment and consistent use of grading systems across samples is critical to understanding these contributions moving forward.

Although it has not been proven, it is possible that misclassification of grading contributes to variations in the reported risk associated with grade. Few studies have rigorously examined concordance between pathologists specifically in applying grading criteria for DCIS. Ringberg *et al*¹⁴ report that the agreement between pathologists was moderate ($\kappa=0.486$) in the SweDCIS trial. Correctness of diagnosis in the subcohort of SweDCIS was 84.8%. In another such study by Sneige *et al*,¹⁵ six surgical pathologists from four institutions used the Lagios grading system to grade 125 DCIS lesions. Before meeting to evaluate the cases, a training set of 12 glass slides, including cases chosen to present conflicting cues for classification, was mailed to the participants with a written criteria summary. This was followed by a working session in which criteria were reviewed and agreed on. The pathologists then graded the

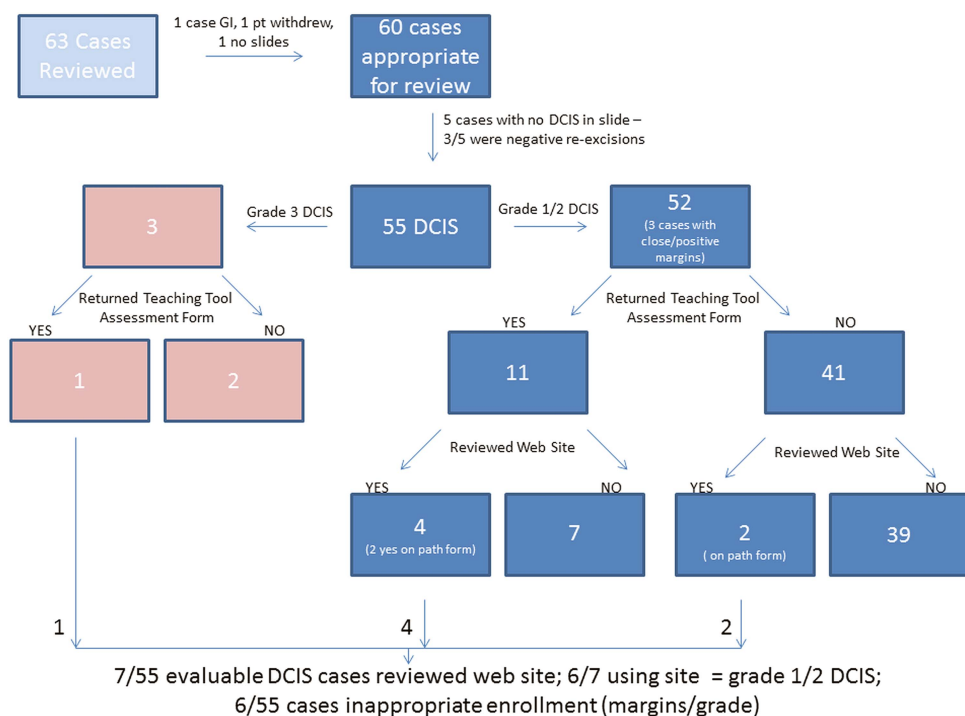


Figure 1 Summary of central review findings GI, gastrointestinal; DCIS, ductal carcinoma in situ.

lesions independently. A complete agreement among raters was achieved in 43 (35%) cases, with five of six raters agreeing in another 45 (36%) cases. In no case did two raters differ by more than one grade. Generalised κ value similarly indicated moderate agreement (0.46, SE=0.02). The authors conclude that with adherence to specific criteria, interobserver reproducibility in the classification of DCIS cases can be obtained in most cases.

By comparison, the pathological assignment of grade in RTOG 98-04 was accurate in 95% of cases, representing excellent concordance. While the pathology tools appeared underused, it is difficult to ascertain whether multiple cases submitted by the same pathologist or institution may have been documented as using the website for the first case and not for subsequent cases. The tool remains an inexpensive, scalable, easily accessible tool online, and may be of use in future studies of intraobserver grading after utilisation. The 5% inaccuracy remains important for this common disease when treatment decisions are based on it. In addition, there is no way to estimate the number of patients inaccurately deemed ineligible based on misclassifying low/intermediate grade lesions as high grade. Finally, of course, grade is not the only criteria needed to accurately assign good risk DCIS. Incorporating data reviewed regarding margin status, the total correctness of diagnosis in the cohort of RTOG 98-04 is 89%, although this may be a low estimate given that the submitted slides may not represent the final margins achieved.

Overall, pathological accuracy on RTOG 98-04 was excellent, but room for improvement remains. Recently the CAP has published guidelines that will assist pathologists in providing clinically useful and relevant information when reporting results of surgical specimen examinations.¹⁷ Moving forward, consideration for requiring use of available tools or real-time central pathology review may be warranted to achieve complete compliance. Clearly, DCIS is a heterogeneous disease, and the ability to predict 'good risk' DCIS depends on reproducible clinicopathological and potentially molecular assessments to best select therapy for these patients.

Take home messages

- Overall, pathological accuracy on RTOG 98-04 was excellent.
- Although underutilized here, the tool developed for RTOG 98-04 remains an inexpensive, scalable, easily accessible Online teaching aid, and may be of use in future studies of intraobserver grading.

Author affiliations

- ¹University of Texas-MD Anderson Cancer Center, Houston, Texas, USA
- ²RTOG Statistical Center, Philadelphia, Pennsylvania, USA
- ³Memorial Sloan-Kettering Cancer Center, New York, New York, USA
- ⁴Sunnybrook Health Sciences Centre, Toronto, Ontario, Canada
- ⁵Massachusetts General Hospital, Boston, Massachusetts, USA
- ⁶University of Michigan Comprehensive Cancer Center, Ann Arbor, Michigan, USA
- ⁷Mount Sinai Medical Center, New York, New York, USA
- ⁸Radiological Associates of Sacramento, Sacramento, California, USA
- ⁹Henry Ford Hospital, Detroit, Michigan, USA
- ¹⁰Cancer Centers of the Carolinas-Greenville CCOP, Greenville, South Carolina, USA
- ¹¹Stephanie Spielman Comprehensive Breast Center, Columbus, Ohio, USA

Contributors The authorship has been reviewed by the RTOG and conforms to the policies of the cooperative group that ran the trial. Specifically: HMK, CH, ER, BLS, LJP, IG, ATP, EMW and DLG contributed to the design and success of the clinical trial from which this correlative report derives and carefully reviewed and contributed to the content of the manuscript. WAW drafted the manuscript and analysed data. NS performed all pathological assessments and reviewed the manuscript. KW performed statistical review, identified cases and reviewed the manuscript. JRW and BMC were primary drafters of the protocol, data collection, oversaw the entire project and contributed to drafting and reviewing the manuscript.

Funding This project was supported by RTOG grants U10 CA21661 and CCOP grant U10 CA37422 from the National Cancer Institute (NCI).

Competing interests None.

Provenance and peer review Not commissioned; externally peer reviewed.

Open Access This is an Open Access article distributed in accordance with the Creative Commons Attribution Non Commercial (CC BY-NC 4.0) license, which permits others to distribute, remix, adapt, build upon this work non-commercially,

and license their derivative works on different terms, provided the original work is properly cited and the use is non-commercial. See: <http://creativecommons.org/licenses/by-nc/4.0/>

REFERENCES

- 1 Lagios MD, Margolin FR, Westdahl PR, *et al.* Mammographically detected duct carcinoma in situ. Frequency of local recurrence following tylectomy and prognostic effect of nuclear grade on local recurrence. *Cancer* 1989;63:618–24.
- 2 Silverstein MJ, Cohan BF, Gerson ED, *et al.* Duct carcinoma in situ: 227 cases without microinvasion. *Eur J Cancer* 1992;28:630–4.
- 3 Solin LJ, McCormick B, Recht A, *et al.* Mammographically detected, clinically occult ductal carcinoma in situ treated with breast-conserving surgery and definitive breast irradiation. *Cancer J Sci Am* 1996;2:158–65.
- 4 Bijker N, Meijnen P, Peterse JL, *et al.* Breast-conserving treatment with or without radiotherapy in ductal carcinoma-in-situ: ten-year results of European Organisation for Research and Treatment of Cancer randomized phase III trial 10853—a study by the EORTC Breast Cancer Cooperative Group and EORTC Radiotherapy Group. *J Clin Oncol* 2006;24:3381–7.
- 5 Bijker N, Peterse JL, Duchateau L, *et al.* Risk factors for recurrence and metastasis after breast-conserving therapy for ductal carcinoma-in-situ: analysis of European Organization for Research and Treatment of Cancer Trial 10853. *J Clin Oncol* 2001;19:2263–71.
- 6 Bijker N, Peterse JL, Duchateau L, *et al.* Histological type and marker expression of the primary tumour compared with its local recurrence after breast-conserving therapy for ductal carcinoma in situ. *Br J Cancer* 2001;84:539–44.
- 7 Correa C, McGale P, Taylor C, *et al.* Overview of the randomized trials of radiotherapy in ductal carcinoma in situ of the breast. *J Natl Cancer Inst Monogr* 2010;2010:162–77.
- 8 Emdin SO, Granstrand B, Ringberg A, *et al.* SweDCIS: Radiotherapy after sector resection for ductal carcinoma in situ of the breast. Results of a randomised trial in a population offered mammography screening. *Acta Oncol* 2006;45:536–43.
- 9 Fisher B, Costantino J, Redmond C, *et al.* Lumpectomy compared with lumpectomy and radiation therapy for the treatment of intraductal breast cancer. *N Engl J Med* 1993;328:1581–6.
- 10 Fisher B, Dignam J, Wolmark N, *et al.* Lumpectomy and radiation therapy for the treatment of intraductal breast cancer: findings from National Surgical Adjuvant Breast and Bowel Project B-17. *J Clin Oncol* 1998;16:441–52.
- 11 Fisher B, Dignam J, Wolmark N, *et al.* Tamoxifen in treatment of intraductal breast cancer: National Surgical Adjuvant Breast and Bowel Project B-24 randomised controlled trial. *Lancet* 1999;353:1993–2000.
- 12 Holmberg L, Garmo H, Granstrand B, *et al.* Absolute risk reductions for local recurrence after postoperative radiotherapy after sector resection for ductal carcinoma in situ of the breast. *J Clin Oncol* 2008;26:1247–52.
- 13 Julien JP, Bijker N, Fentiman IS, *et al.* Radiotherapy in breast-conserving treatment for ductal carcinoma in situ: first results of the EORTC randomised phase III trial 10853. EORTC Breast Cancer Cooperative Group and EORTC Radiotherapy Group. *Lancet* 2000;355:528–33.
- 14 Ringberg A, Nordgren H, Thorstenson S, *et al.* Histopathological risk factors for ipsilateral breast events after breast conserving treatment for ductal carcinoma in situ of the breast—results from the Swedish randomised trial. *Eur J Cancer* 2007;43:291–8.
- 15 Sneige N, Lagios MD, Schwartz R, *et al.* Interobserver reproducibility of the Lagios nuclear grading system for ductal carcinoma in situ. *Hum Pathol* 1999;30:257–62.
- 16 Committee TCC. Consensus conference on the classification of ductal carcinoma in situ. *Cancer Epidemiol Biomarkers Prev* 1997;80:1789–802.
- 17 Lester SC, Bose S, Chen YY, *et al.* Protocol for the examination of specimens from patients with invasive carcinoma of the breast. *Arch Pathol Lab Med* 2009;133:1515–38.
- 18 Fisher ER, Dignam J, Tan-Chiu E, *et al.* Pathologic findings from the National Surgical Adjuvant Breast Project (NSABP) eight-year update of Protocol B-17: intraductal carcinoma. *Cancer* 1999;86:429–38.
- 19 Solin LJ, Kurtz J, Fourquet A, *et al.* Fifteen-year results of breast-conserving surgery and definitive breast irradiation for the treatment of ductal carcinoma in situ of the breast. *J Clin Oncol* 1996;14:754–63.
- 20 Wallis MG, Clements K, Kearins O, *et al.* The effect of DCIS grade on rate, type and time to recurrence after 15 years of follow-up of screen-detected DCIS. *Br J Cancer* 2012;106:1611–17.
- 21 Dignam JJ, Bryant J, Wieand HS, *et al.* Early stopping of a clinical trial when there is evidence of no treatment benefit: protocol B-14 of the National Surgical Adjuvant Breast and Bowel Project. *Control Clin Trials* 1998;19:575–88.
- 22 Rudloff U, Jacks LM, Goldberg JL, *et al.* Nomogram for predicting the risk of local recurrence after breast-conserving surgery for ductal carcinoma in situ. *J Clin Oncol* 2010;28:3762–9.
- 23 Yi M, Meric-Bernstam F, Kuerer HM, *et al.* Evaluation of a breast cancer nomogram for predicting risk of ipsilateral breast tumor recurrences in patients with ductal carcinoma in situ after local excision. *J Clin Oncol* 2012;30:600–7.

Supplemental Methods

Specimen Handling Guidelines provided in RTOG 98-04:

A flow diagram for this procedure is outlined in Figure 1. The breast specimen when received should be measured and grossly inspected for any orientation designated by the surgeon. The specimen, still intact, should be placed on an x-ray plate and a radiograph should be taken. The radiograph should be evaluated with comparison to the patient's mammogram, which showed the suspicious microcalcifications and/or abnormal soft tissue densities (*ASTD*). This is best evaluated by a radiologist. If calcification/*ASTD* are identified which correspond to those observed mammographically, the surgeon should be informed immediately as the procedure is finished. If no calcifications or *ASTDs* corresponding to those seen on mammogram are identified, then a second radiograph of serial sections should be reviewed before proceeding with any further surgery. The oriented breast specimen should then be inked (*multiple colors may be used to identify various margins of resection.*) Tissue is sequentially sectioned in 3-5 mm thick sections and laid down, in order, on an x-ray plate (*keeping coherent orientation*). A second radiograph is taken and evaluated for the presence of microcalcifications and/or *ASTDs*. If calcifications or *ASTDs* corresponding to the mammogram are not identified, additional tissue must be removed after relocalization procedure. If corresponding calcifications or *ASTDs* are identified, no further procedure is required. It is strongly suggested that no frozen sections of these tissue specimens be performed (*unless an identifiable lesion of adequate size [more than 1 cm] becomes apparent with serial sectioning*). These specimens should be examined on permanent sections. For relatively small specimens (*less than 5 cm in diameter*), all of the tissue specimen can be easily submitted for evaluation. Comparison of serial tissue sections with the corresponding radiograph should allow identification of tissue segments, which contain microcalcifications and/or *ASTDs*. The cassettes into which these areas are submitted should be identified in the gross dictation. For larger specimens, permanent sections should include 1) all areas containing microcalcifications and/or *ASTDs*; 2) all areas of fibrous parenchymal tissue 3) tissue margins of resection.