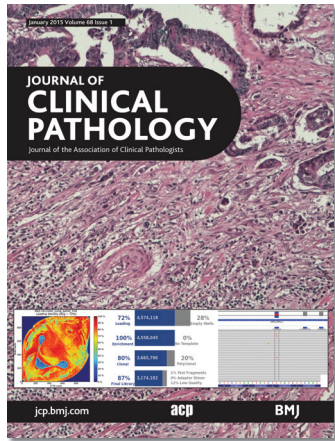

Journal of Clinical Pathology



Cover legend: An Ion Torrent sequencing run showing loading density, performance parameters carried out using a 316 chip and observed with an integrated genetics viewer, in a case of colorectal cancer with low frequency of a KRAS Q22K mutant allele. See page 66.

Receive regular table of contents by email.
Register using this QR code.



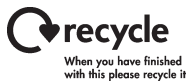This article has been chosen by the Editor to be of special interest or importance and is freely available online.



Articles carrying the Unlocked Logo are freely available online under the BMJ Journals unlocked scheme. See <http://jcp.bmj.com/info/unlocked.dtl>

C O P E COMMITTEE ON PUBLICATION ETHICS


This journal is a member of and subscribes to the principles of the Committee on Publication Ethics
www.publicationethics.org



MCQs The online version of this article contains multiple choice questions hosted on BMJ Learning.

Contents



Best practice

- 1  Laboratory clues to immunodeficiency; missed chances for early diagnosis? *P D Bright, N Rooney, P F Virgo, R J Lock, S L Johnston, D J Unsworth*

Original articles

- 6 Sonic hedgehog signalling proteins are frequently expressed in retinoblastoma and are associated with aggressive clinicopathological features
J-Y Choe, J Y Yun, Y K Jeon, S H Kim, H-K Choung, S Oh, M Park, J E Kim
- 12 PAX-8 expression in renal tumours and distant sites: A useful marker of primary and metastatic renal cell carcinoma?
M L Barr, L B Jilaveanu, R L Camp, A J Adeniran, H M Kluger, B Shuch
- 18 Pulmonary hypertensive vascular changes in lungs of patients with sudden unexpected death. Emphasis on congenital heart disease, Eisenmenger syndrome, postoperative deaths and death during pregnancy and postpartum
D Kresxi, M N Sheppard
- 22 Comparative validation of assessment criteria for Crohn-like lymphoid reaction in colorectal carcinoma
J H Kim, K-J Kim, J M Bae, Y-Y Rhee, N-Y Cho, H S Lee, G H Kang
- 29  Sprue-like histology in patients with abdominal pain taking olmesartan compared with other angiotensin receptor blockers
S M Lagana, E D Braunstein, C Arguelles-Grande, G Bhagat, P H R Green, B Lebowitz
- 33 Validation of whole slide imaging in the primary diagnosis of gynaecological pathology in a University Hospital
J Ordí, P Castillo, A Saco, M del Pino, O Ordí, L Rodríguez-Carunchio, J Ramírez
- 40 KIR genotype distribution among symptomatic patients with and without *Helicobacter pylori* infection: is there any role for the B haplotype?
R Mahfouz, R Hoteit, N E Hajj, D Shammaa, A I Sharara

January 2015 Volume 68 Issue 1

- 44 The utility of ERG, CD31 and CD34 in the cytological diagnosis of angiosarcoma: an analysis of 25 cases
H C Sullivan, M A Edgar, C Cohen, C K Kovach, K HooKim, M D Reid
- 51  Ultrastructural features of eosinophilic oesophagitis: impact of treatment on desmosomes
K E Capocelli, S D Fernando, C Menard-Katcher, G T Furuta, J C Masterson, E P Warchow
- 57 Molecular pathology analyses of two fatal human infections of avian influenza A(H7N9) virus
Y Feng, L Hu, S Lu, Q Chen, Y Zheng, D Zeng, J Zhang, A Zhang, L Chen, Y Hu, Z Zhang
- 64 Ion Torrent next-generation sequencing for routine identification of clinically relevant mutations in colorectal cancer patients
U Malapelle, E Vigiari, R Sgariglia, C Bellicivine, L Colarossi, D Vitale, P Pallante, G Troncone
- 69 Genetic basis of persistent red blood cell microcytosis in the Chinese unexplained by phenotypical testing
C-C So, A K Liu, M H Tsang, D Y Ngai, K-S Leung, A Y Chan
- 73  Endotoxin detection in end-stage kidney disease
J Wong, H Jeraj, E Vilar, A Viljoen, K Farrington

Short reports

- 79 Is neuroendocrine differentiation useful to discriminate primary sinonasal intestinal-type adenocarcinomas from metastatic colorectal adenocarcinomas?
F Progetti, E Serrano, S Vergez, A-C Bissainthe, M-B Delisle, E Uro-Coste
- 83 KRAS mutation status impacts diagnosis and treatment decision in a patient with two colon tumours: a case report
X Li, G Pezeshkpour, R T Phan
- 86 hMSH6: a potential diagnostic marker for oral carcinoma in situ
M Jessri, A J Dalley, C S Farah

PostScript

- 91 Thank you to our reviewers 2014