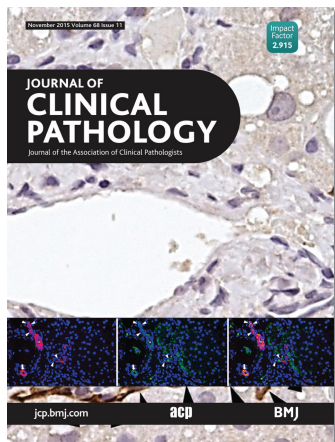


Journal of Clinical Pathology



Cover legend: Double-labeling of cytokeratin (CK)-19 and epithelial cell adhesion molecule (EpCAM) in non-alcoholic fatty liver disease (NAFLD) from S Carotti *et al*, page 883–890.

Receive regular table of contents by email.
Register using this QR code.



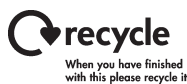This article has been chosen by the Editor to be of special interest or importance and is freely available online.



Articles carrying the Unlocked Logo are freely available online under the BMJ Journals unlocked scheme.
See <http://jcp.bmj.com/info/unlocked.dtl>

C O P E COMMITTEE ON PUBLICATION ETHICS

This journal is a member of and subscribes to the principles of the Committee on Publication Ethics
www.publicationethics.org



MCQs The online version of this article contains multiple choice questions hosted on BMJ Learning.

Contents

Reviews

- 859** Contribution of microRNA analysis to characterisation of pancreatic lesions: a review *M Visani, G Acquaviva, S Fiorino, M L B Reggiani, M Masetti, E Franceschi, A Fornelli, E Jovine, C Fabbri, A A Brandes, G Tallini, A Pession, D de Biase*
- 870** Flow cytometry for the microscopy of body fluids in patients with suspected infection *G E Bignardi*
- 879** Getting controls under control: the time is now for immunohistochemistry *E E Torlakovic, S Nielsen, M Vyberg, C R Taylor*

Original articles

- 883** Portal inflammation during NAFLD is frequent and associated with the early phases of putative hepatic progenitor cell activation *S Carotti, U Vespasiani-Gentilucci, G Perrone, A Picardi, S Morini*
- 891** Microvascular proliferation in luminal A and basal-like breast cancer subtypes *M R Kraby, K Krüger, S Opdahl, L J Vatten, L A Akslen, A M Bofin*
- 898** Non-infectious aortitis of the ascending aorta: a histological and clinical correlation of 71 cases including overlap with medial degeneration and atheroma—a challenge for the pathologist *C Ryan, A Barbour, L Burke, M N Sheppard*
- 905** Twist predicts poor outcome of patients with astrocytic glioma *K Nordfjors, J Haapasalo, K Mäkelä, K J Granberg, M Nykter, M Korja, T Paavonen, H Haapasalo, Y Soini*
- 913** New tumour antigen PLAC1/CP1, a potentially useful prognostic marker and immunotherapy target for gastric adenocarcinoma *F Liu, D Shen, X Kang, C Zhang, Q Song*

November 2015 Volume 68 Issue 11

- 917** Plasma levels of matrix metalloproteinase-2 and -9 in male and female patients with cirrhosis of different aetiologies *C-Y Huang, K-C Tseng, M-N Lin, J-P Tsai, C-C Su*
- 923** Clinical use of low haemoglobin density, transferrin saturation, bone marrow morphology, Perl's stain and other plasma markers in the identification of treatable anaemia presenting for cardiac surgery in a prospective cohort study *P Martin-Cabrera, M Hung, E Ortmann, T Richards, M Ghosh, F Bottrill, T Collier, A A Klein, M W Besser*

Short reports

- 931** Decreased faux addenda following standardisation of pathologist practice *M L Smith, A J Wendel-Spiczka, M A Zarka*
- 935** A template for a clinico-pathological audit of medical liver biopsies *R Colling, E Fryer, J Cobbold, J Collier, E Collantes, L M Wang, S Hubscher, J Wyatt, K Fleming*
- 938** In the era of the 24 h laboratory, does communicating Gram stain results from blood cultures flagging positive outside of conventional working hours alter patient management? *J S Moore, R J Koerner*

PostScript

- 942** Correspondence
- 950** Letter to the Editor

Correction

- 912** Correction