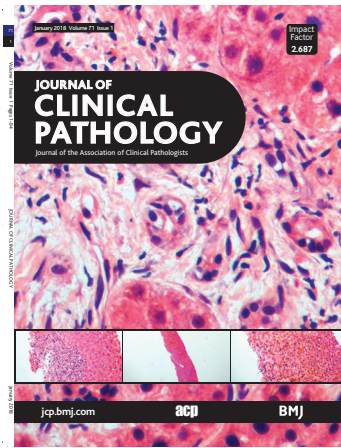


Journal of Clinical Pathology



Cover legend: Liver allograft biopsies with histological cholestasis: portal tract oedema, ductular proliferation; cellular rejection with inflammatory infiltrates and bile accumulation.

Contents

Gene of the month

- 1 Rnf43
S Serra, R Chetty

Review

- 7 The third pathway of colorectal carcinogenesis
C A Rubio, G Puppa, G de Petris, L Kis, P T Schmidt

Original articles

- 12 Clinical associations of the positive anti Ro52 without Ro60 autoantibodies: undifferentiated connective tissue diseases
S H K Mung, M Thomas
- 20 An evaluation of a coagulation system (Xprecia Stride) for utilisation in anticoagulation management
D McCahon, A Roalfe, D A Fitzmaurice
- 27 How can we ensure that the coroner's autopsy is not an invasion of human rights?
S Leadbeater, R James
- 34 Prognostic value of vitamin D receptor and insulin-like growth factor receptor 1 expression in triple-negative breast cancer
M Soljic, I Mrklic, S Tomic, T Omrcen, N Sutalo, M Bevanda, E Vrdoljak
- 40 Cervical intraepithelial neoplasia (CIN) in African women living with HIV: role and effect of rigorous histopathological review by a panel of pathologists in the HARP study endpoint determination
S Doutre, T Omar, O Gombri-Lompo, H Kelly, O Clavero, S Zan, A Chikandiwa, B Sawadogo, S Delany-Morethwe, V Costes, P Mayaud, M Segondy, on behalf of the HARP Study Group
- 46 PD-L1 protein expression in tumour cells and immune cells in mismatch repair protein-deficient and -proficient colorectal cancer: the foundation study using the SP142 antibody and whole section immunohistochemistry
T El Jabbour, J S Ross, C E Sheehan, K E Affolter, K B Geiersbach, A Boguniewicz, S Ainechi, M P Brouner, D M Jones, H Lee
- 52 TP73 DNA methylation and upregulation of Δ Np73 are associated with an adverse prognosis in breast cancer
L C Gomez, M L Sotile, M E Guerrero-Gimenez, F C M Zoppino, A L Redondo, F E Gago, J I Orozco, O M Tello, M Roqué, S B Nadin, D M Marzese, L M Vargas-Roig

January 2018 Volume 71 Issue 1

- 59 Seasonality in airborne bacterial, fungal, and (1 \rightarrow 3)- β -D-glucan concentrations in two indoor laboratory animal rooms
S Hwang, Y Ko, D Park, C Yoon
- 67 Autopsy interrogation of emergency medicine dispute cases: how often are clinical diagnoses incorrect?
D Liu, R Gan, W Zhang, W Wang, H Saiyin, W Zeng, G Liu
- 72 Liver allograft biopsies with histological cholestasis: a clinicopathological study of 254 cases from a single centre
R Cheuk-lam Lo, K Kwan-shuen Chan, K Siu-ho Chok, I Oi-lin Ng

Short reports

- 79 Hb Baden: a rare high affinity haemoglobin variant and its management
J Lee, C N Harrison
- 81 Unexplained abnormal liver function in patients with primary antibody deficiency: could it be chronic hepatitis E infection?
O E Mohamed, J Jones, H Osman, A P Huissoon
- 84 Incidental detection of germline variants of potential clinical significance by massively parallel sequencing in haematological malignancies
C K Yamakou, K Jones, G L Ryland, E R Thompson, G Reid, M McBean, A Trainer, D Westerman, P Blombery

Molecules in pathogenesis

- 88 Subcellular localisation of the stem cell markers OCT4, SOX2, NANOG, KLF4 and c-MYC in cancer: a review
B van Schaijk, P F Davis, A C Wickremesekera, S T Tan, T Iintiang

Virtual case of the month

- 92 Crouching tiger, hidden dragon
D Hopkins, M Varma

PostScript

- 93 Correspondence

Electronic pages

- e1 Correspondence



This article has been chosen by the Editor to be of special interest or importance and is freely available online.



Articles carrying the Unlocked Logo are freely available online under the BMJ Journals unlocked scheme. See <http://authors.bmj.com/open-access/>



This journal is a member of and subscribes to the principles of the Committee on Publication Ethics www.publicationethics.org



When you have finished with this please recycle it

MCQs The online version of this article contains multiple choice questions hosted on BMJ Learning.