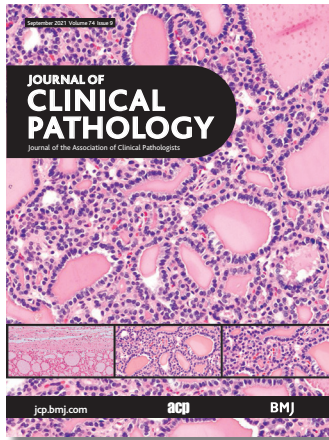

# Journal of Clinical Pathology



Cover legend: Highly differentiated thyroid follicular carcinoma of ovarian origin.

## Contents

### Gene of the month

- 543** Gene of the month: lymphocyte-activation gene 3 (LAG-3)  
*M P Lythgoe, D S K Liu, N E Annels, J Krell, A E Frampton*

### Molecules in pathogenesis

- 548** Protein tyrosine phosphatase receptor type C (PTPRC or CD45)  
*M A Al Barashdi, A Ali, M F McMullin, K Mills*

### Viewpoint

- 553** Highly differentiated follicular thyroid-type carcinoma of the ovary reconsidered  
*L M Roth, B Czernobilsky, D J Roth, L Cheng*

### Review

- 559** Significance of adenosquamous proliferation in breast lesions  
*M J Wilsher*

### Best practice

- 568** Some undesirable traps which can mislead the pathologist  
*V Mercier, M Sasso, P Kouyoumdjian, D Sizaret, S Benzimra, S Gonzalez, G Desoubreaux*

### Original research

- 571** Adiponectin and adiponectin receptor 1 expression proteins levels are modified in breast cancer in postmenopausal women with obesity  
*L Orozco-Arguelles, S De los Santos, A Tenorio-Torres, J P Méndez, M Leal-García, R Coral-Vázquez, C Vega-García, V Bautista-Piña, M E Tejada, E Cárdenas-Cárdenas, P Canto*

- 577** Asymmetric crypt fission in colectomy specimens in patients with ulcerative colitis  
*C A Rubio, P T Schmidt*

## September 2021 Volume 74 Issue 9

- 582** Positivity for SATB2 distinguishes Islet1 positive rectal neuroendocrine tumours from pancreaticoduodenal neuroendocrine tumours  
*S K Mohanty, A Tiwari, N Bhardwaj, F Chuang, E Kim, H Lugo, X Yuan, S A Diffalha, M Peralta-Venturina, B Balzer, D Dhall*

- 589** Prognostic values of L-type amino acid transporter 1 and CD98hc expression in breast cancer  
*M Ichinoe, T Mikami, N Yanagisawa, T Yoshida, K Hana, H Endou, I Okayasu, N Sengoku, H Ogata, M Saegusa, K Shibuya, Y Murakumo*

- 596** Implementing NGS-based *BRCA* tumour tissue testing in FFPE ovarian carcinoma specimens: hints from a real-life experience within the framework of expert recommendations  
*D Rivera, M Paudice, V Gismondi, G Anselmi, V G Vellone, L Varesco, on behalf of the Ligurian BRCA Working Group*

### Short reports

- 604** Idylla microsatellite instability assay versus mismatch repair immunohistochemistry: a retrospective comparison in gastric adenocarcinoma  
*L Farnkiss, I Hopkins, M Jones*

- 608** Observations from a teaching hospital in Ireland: changing from MDRD to CKD-EPI eGFR in routine practice  
*J L V Reeve, M Davis, P J Twomey*


### PostScript


- 612** Brain autopsies in fatal COVID-19 and postulated pathophysiology: more puzzling than a Rubik's cube  
*S Mehta, S Bhandari, S Mehta*

- 614** Cross-reactivity of SARS-CoV-2 with HIV chemiluminescent assay leading to false-positive results  
*S S Tan, K L Chew, S Saw, R Jureen, S Sethi*

### Electronic page

- e13** Intrapulmonary tumour showing recent growth  
*J Laforga, L Andreo*

 This article has been chosen by the Editor to be of special interest or importance and is freely available online.


 Articles carrying the Unlocked Logo are freely available online under the BMJ Journals unlocked scheme. See <http://authors.bmj.com/open-access/>

C O P E  
Member since 2008  
JMB0016

This journal is a member of and subscribes to the principles of the Committee on Publication Ethics  
[www.publicationethics.org](http://www.publicationethics.org)

 **recycle**

When you have finished with this please recycle it

 The online version of this article contains multiple choice questions hosted on BMJ Learning.