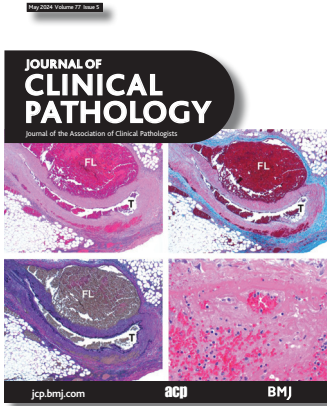



Cover legend: Histological images of the obtuse marginal artery at $\times 40$ magnification with H&E stain (A), trichrome stain (B) and elastic stain (C) showing acute arterial dissection with blood in the false lumen (FL) which is compressing the true lumen (T). At higher ($\times 400$) magnification the blood in the false lumen contains acute thrombus (D).

Contents

Gene of the month

- 291 Gene of the month: the uroplakins
K Sivakumaar, J Griffin, E Schofield, J W F Catto, I Jubber

Grand rounds

- 297 Sudden unexpected death in a middle-aged woman
F V C Casimero, E D Patalas, J R Stone

Grand rounds commentary

- 301 Commentary on sudden unexpected death in a middle-aged woman: spontaneous coronary artery dissection (SCAD), myocardial infarction and cardiac biomarkers
P Collinson

- 303 Invited commentary on: sudden cardiac death
M C Bois, M D.

PostScript

- 304 Investigating the relative frequencies of unascertained causes of death and advanced decomposition at autopsy
T Estrin-Serlui, J Yoon, M Osborn

Original research

- 306 Cystic neutrophilic granulomatous mastitis: sensitivity and specificity of 16s rRNA and Sanger sequencing for *Corynebacterium* spp
E Yang, R Kozak, S Nofech-Mozes, E Salvant, E Olkhov-Mitsel, E Slodkowska, A Plotkin, W Hanna, F-I Lu

- 312 Reducing workload in malignant melanoma sentinel node examination: a national study of pathology reports from 507 melanoma patients
C Mellemegaard, I J Christensen, G Salkus, P Wirenfeldt Staun, N Korsgaard, K Hein Lindahl, M Skaarup Larsen, S Klausen, J Lade-Keller

May 2024 Volume 77 Issue 5

- 318 From Castleman disease histopathological features to idiopathic multicentric Castleman disease: a multiparametric approach to exclude potential iMCD histopathological mimickers
L Rodriguez Merino, A A Pomares, J R Arce, S Montes-Moreno

- 324 Primary salivary duct carcinoma of the lung: clinicopathological features, diagnosis and practical challenges
S Li, L Hou, Y Huang, W Wu, C Wu, L Zhang

- 330 Lipid droplets' functional protein caveolin-2 is associated with lipid metabolism-related molecule FABP5 and EMT marker E-cadherin in oral epithelial dysplasia
X-J Chen, Y-T Bai, J-R Xie, G Zhou


- 338 Correlation of immediate prevalence of cervical precancers and cancers with HPV genotype and age in women with ASC-US/hrHPV+: a retrospective analysis of 2292 cases
Q Liu, T Zhang, L Chen, X Zhou, X Zhang, W Zheng, S Niu, F Zhou


- 343 Circulating IL-6 is associated with disease progression in BRAFwt metastatic melanoma patients receiving anti-PD-1 therapy
K Mirjačić Martinović, A Vuletić, N Tišma Miletić, S Matković, D Gavrilović, A Ninković, V Jurišić, N Babović

Short reports

- 352 Dematiaceous fungal infections: clinical and pathologic conundrums
E M Harsough, R K Foreman, M Martinez-Lage, J Branda, A R Sohani, L Zukerberg

- 358 Rare myxoid pleomorphic liposarcoma: a case report and literature review
Y Shen, L Zhao, A Li, Q Peng, Q Liu, L Wang, Z Liu


 This article has been chosen by the Editor to be of special interest or importance and is freely available online.

 Articles carrying the Unlocked Logo are freely available online under the BMJ Journals unlocked scheme. See <http://authors.bmj.com/open-access/>

C O P E
Member since 2008
JM00016

This journal is a member of and subscribes to the principles of the Committee on Publication Ethics
www.publicationethics.org

 **recycle**
When you have finished with this please recycle it

 The online version of this article contains multiple choice questions hosted on BMJ Learning.