

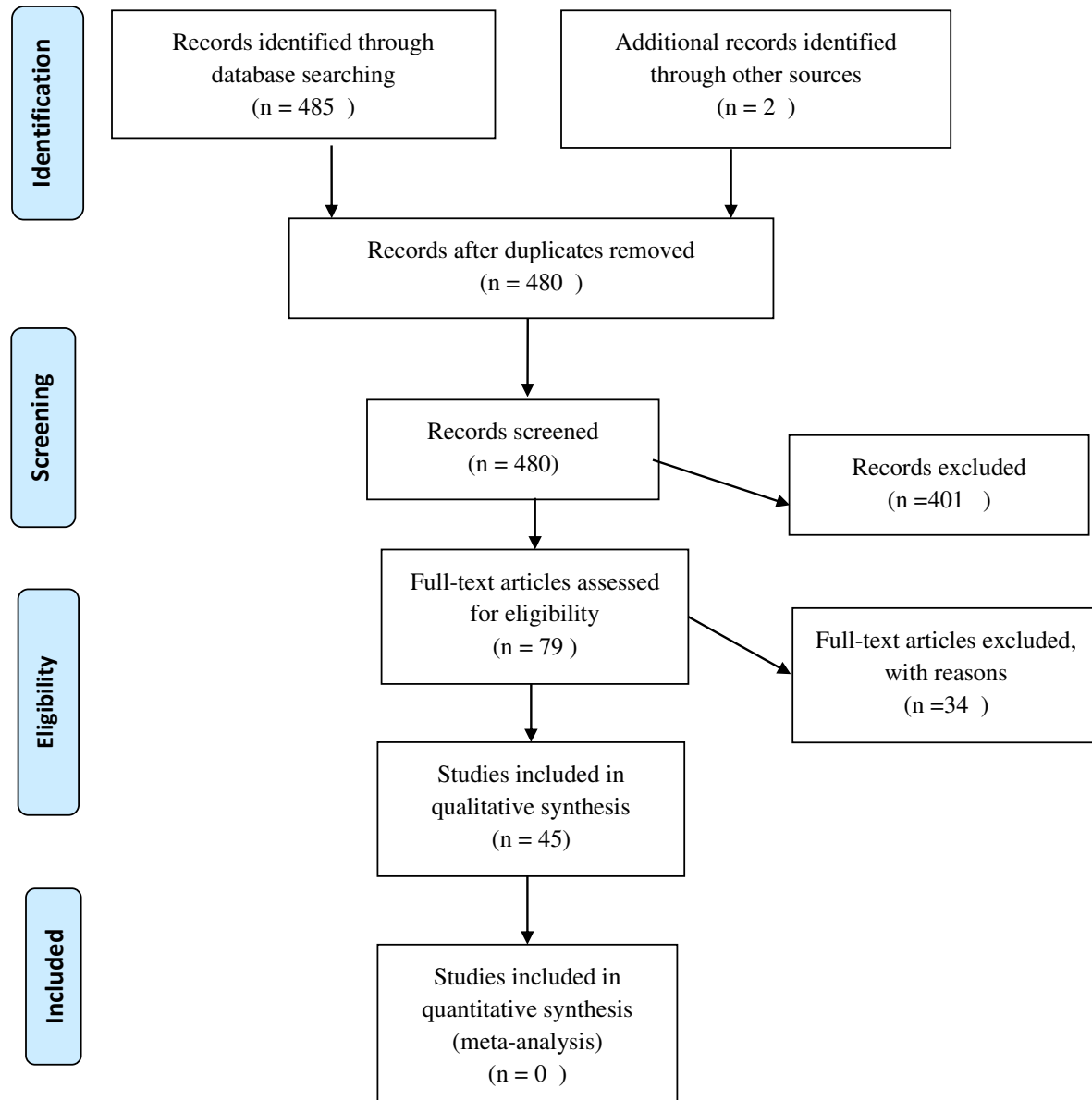
Supplementary Table: Flow Diagram for Selection of Studies (PRISMA):

Table 1: Important Histo-pathological findings of systems/organs observed by authors in different studies:

| S.N | Histo-pathological Findings | Authors |
|-----|---|---|
| | Respiratory System-Lung | |
| 1. | <ul style="list-style-type: none"> • Alveoli: Damaged or atypical enlarged pneumocytes with large nuclei, type II pneumocyte hyperplasia, diffuse alveolar damage (DAD), focal sloughing, hyaline membrane formation, intra-alveolar hemorrhage, intra-alveolar neutrophil infiltration, amphophilic granular cytoplasm, and prominent nucleoli characteristic of viral cytopathic-like changes. • Vessels: Edematous and congested vessels, plug formation, fibrinoid necrosis of the small vasculature, hyaline thrombi in micro vessels. Significant deposits of complements- C5b-9 (membrane attack complex), C4d, and mannose binding lectin (MBL)-associated serine protease (MASP)2, in the microvasculature. • Cellular components: Presence of syncytial giant cells, focal infiltration of immune and inflammatory (lymphocytes and monocytes) and increased stromal cells. • Ultrastructural changes: Viral particles in bronchial mucosal epithelia and type II alveolar epithelia. | Tian S et al, Barton LM et al, Xu Z et al, Luo W et al, Yao XH, Magro C et al, Bradley BT et al |
| | Urinary System-Kidney | |
| 2. | <ul style="list-style-type: none"> • Glomerulus: Ischemic changes, podocyte vacuolation, focal segmental glomerulosclerosis, accumulation of plasma in Bowman's space. • Renal tubules: Loss of brush border in proximal tubule, non-isometric vacuolar degeneration, and necrosis, edematous epithelial cells. • Vessels: Erythrocyte aggregates obstructing the lumen of capillaries without platelet or fibrinoid material with occasional hemosiderin granules and pigmented casts, hyalinosis of arteriole, arteriosclerosis of medium sized arteries, fibrin thrombus, shrinkage of capillary loops in glomeruli. | Yao XH et al, Su H et al, Tietäväinen J et al, Grimes et al, Bradley BT et al |

| | | |
|----|--|--|
| | <ul style="list-style-type: none"> • Ultrastructural changes: Clusters of viral particles with distinctive spikes in the tubular epithelium and podocytes. | |
| | Gastro Intestinal System | |
| 3. | <ul style="list-style-type: none"> • Liver:Focal macro vesicular steatosis, nuclear glycogen accumulation in hepatocytes, dense atypical small lymphocytes in portal tracts.Regenerative nodules and thick fibrous bands, Mild zone 3 sinusoidal dilatation, mild lobular lymphocytic infiltration. Patchy hepatic necrosis in the periportal and centrilobular areas.Hepatic cell degeneration and focal necrosis, biliary plugs in the small bile duct. • Esophagus: Occasional lymphocytic infiltration in the esophageal squamous epithelium. • Stomach: Partial epithelial degeneration, necrosis and shedding of the gastric mucosa. Dilatation and congestion of small blood vessels and edema of lamina propria and submucosa with infiltration of immune cells (as lymphocytes, monocytes, and plasma cells). • Intestine:Stenosis of the small intestine and segmental dilatation. Numerous infiltrating plasma cells and lymphocytes with interstitial oedema in the lamina propria. • Pancreas: Degeneration of the cells of islets. | Tian S et al, Yao XH et al, Liu Q et al ,Xiao F et al |
| | Cardio Vascular System | |
| 4. | <ul style="list-style-type: none"> • Foci of lymphocytic inflammation, • Acute myocyte necrosis • Presence of inflammatory cells and apoptotic bodies • Ultrastructural observation:Viral inclusion bodies in vascular endothelial cells. • Immunohistochemistry: Presence of CD61+ megakaryocytes In purpuric-papulo-vesicular | Tian S et al, Bradley BT et al, Wichmann et al, Tavazzi et al, Yao XH et al, Varga et al, Fox et al, Gianotti, Zerbi, and Dodiuk-Gad, Kolivras et al, Varga et al. |
| | Reproductive System | |
| 5. | <ul style="list-style-type: none"> • Thickened basement membrane with peritubular fibrosis and vascular congestion • Leukocyte infiltration • Extensive germ cell destruction was. • TUNEL assay: Increased apoptotic spermatogonic cells. | Jian Xu et al , Chen F et al |
| | Nervous System | |

| | | |
|---|--|--|
| 6. | <ul style="list-style-type: none"> • Acute hypoxic ischemic injury, hyperemia, edema, and neuronal degeneration • CT, MRI: Ischemia and/or hemorrhage, and enhanced cortical/subcortical grey matter and fiber tracts • SARS-CoV-2 RNA was detected in the brain tissue and cerebrospinal fluid in some patients. | Solomon, I. H. et al, Mahammedi A et al, Moriguchi T et al |
| Histo-pathological Findings (Skin) | | |
| 7. | <ul style="list-style-type: none"> • Vessels: Perivascular inflammatory cells, intraluminal thrombi. • Epidermis: Parakeratosis, acanthosis, dyskeratotic keratinocytes, necrotic keratinocytes, acantholytic clefts, lymphocyte satellitosis and pseudoherpetic • Immunohistochemistry: ACE-2 positivity in basal layer of cells in hair follicle, sebaceous glands, smooth muscle cells. | I Hamming et al, Gianotti R et al, Kolivras A et al. |