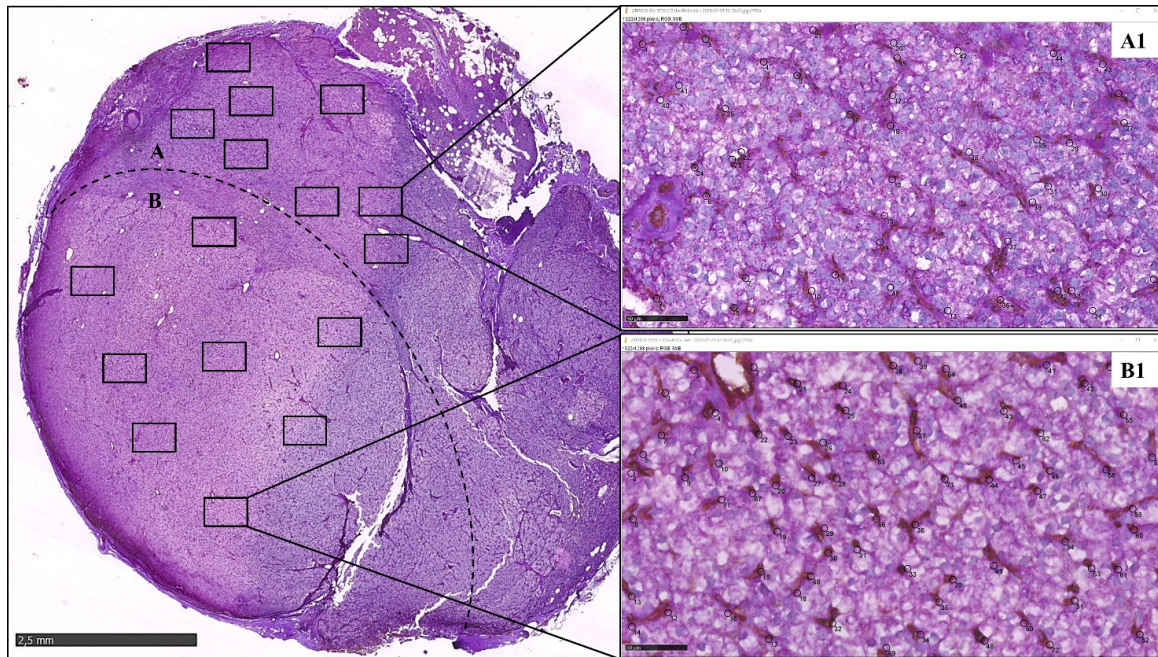


**Fig. S1**

**Fig S1.** Atypical tumor, CD31/PAS double staining. In this section, vessels are not uniformly distributed: the dashed line defines two areas: area A in which mosaic vessels with intermittent CD31/PAS+ Immunoreactivity are prevalent, and area B in which classic CD31+/PAS+ vessels are the most representative.

In each area 8 fields at X40 in high density («hot spot») zones for each type of vessel, were selected and vessels were counted with Image J (A1 and B1)