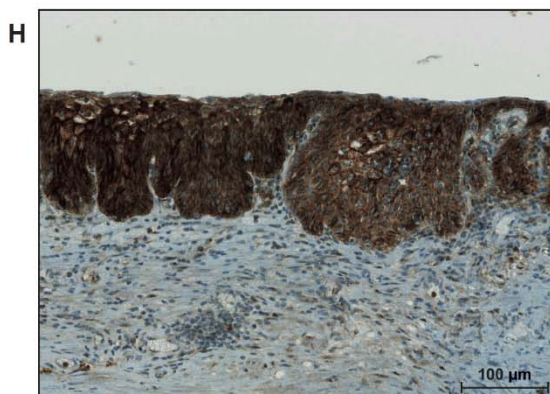
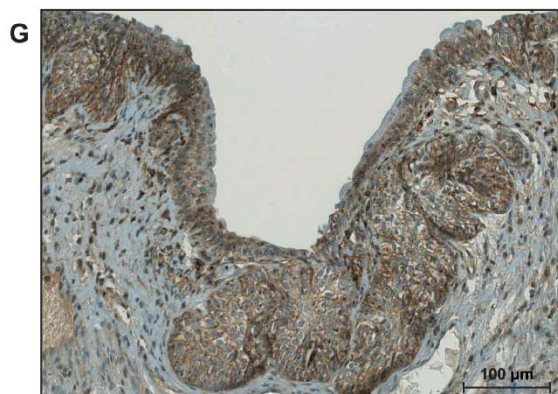
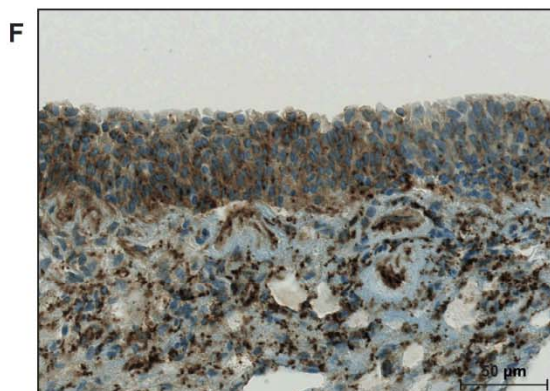
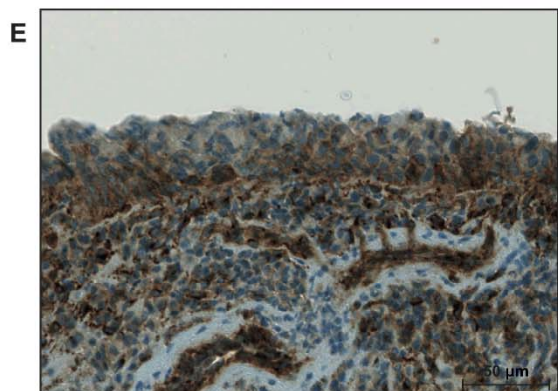
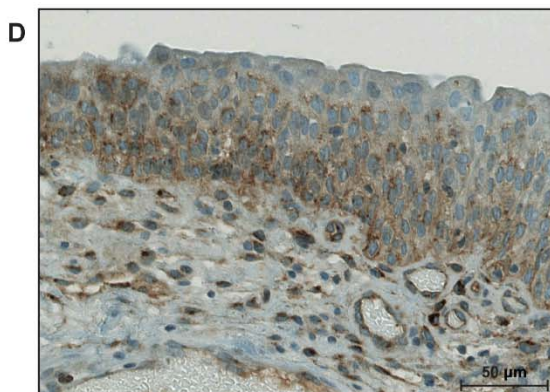
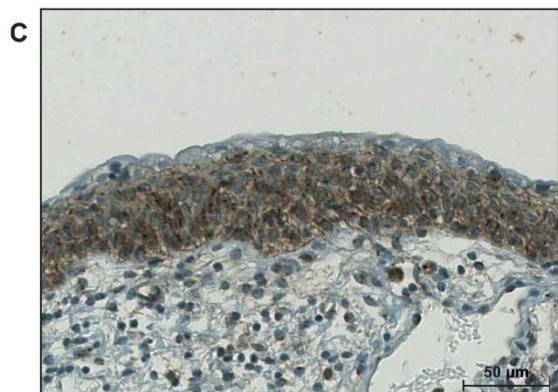
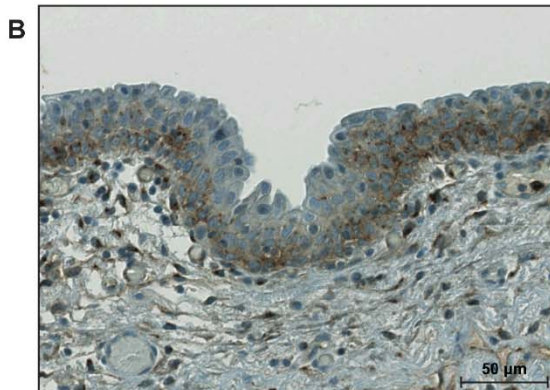
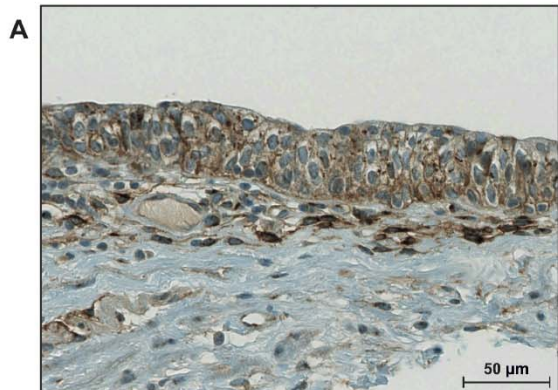


Supplemental Figure 1: Immunohistochemical staining with Cx43 in non-dysplastic urothelium, weak but consistent staining was observed in 7 out of 8 samples in the basal and intermediate layers (**A-F**) as well as in Brunn's nests (**G**). One single sample showed a strong Cx43 staining intensity (**H**). Urothelial umbrella cells at the surface were negative for Cx43 for all cases.



Supplemental Figure 2: Kaplan-Meier analyses for progression-free survival (A) and for recurrence-free survival (B) for Cx43 staining ($n=40$) in patients with pT1 high grade tumours. For statistical analysis for survival curves Log-Rank test was used.

